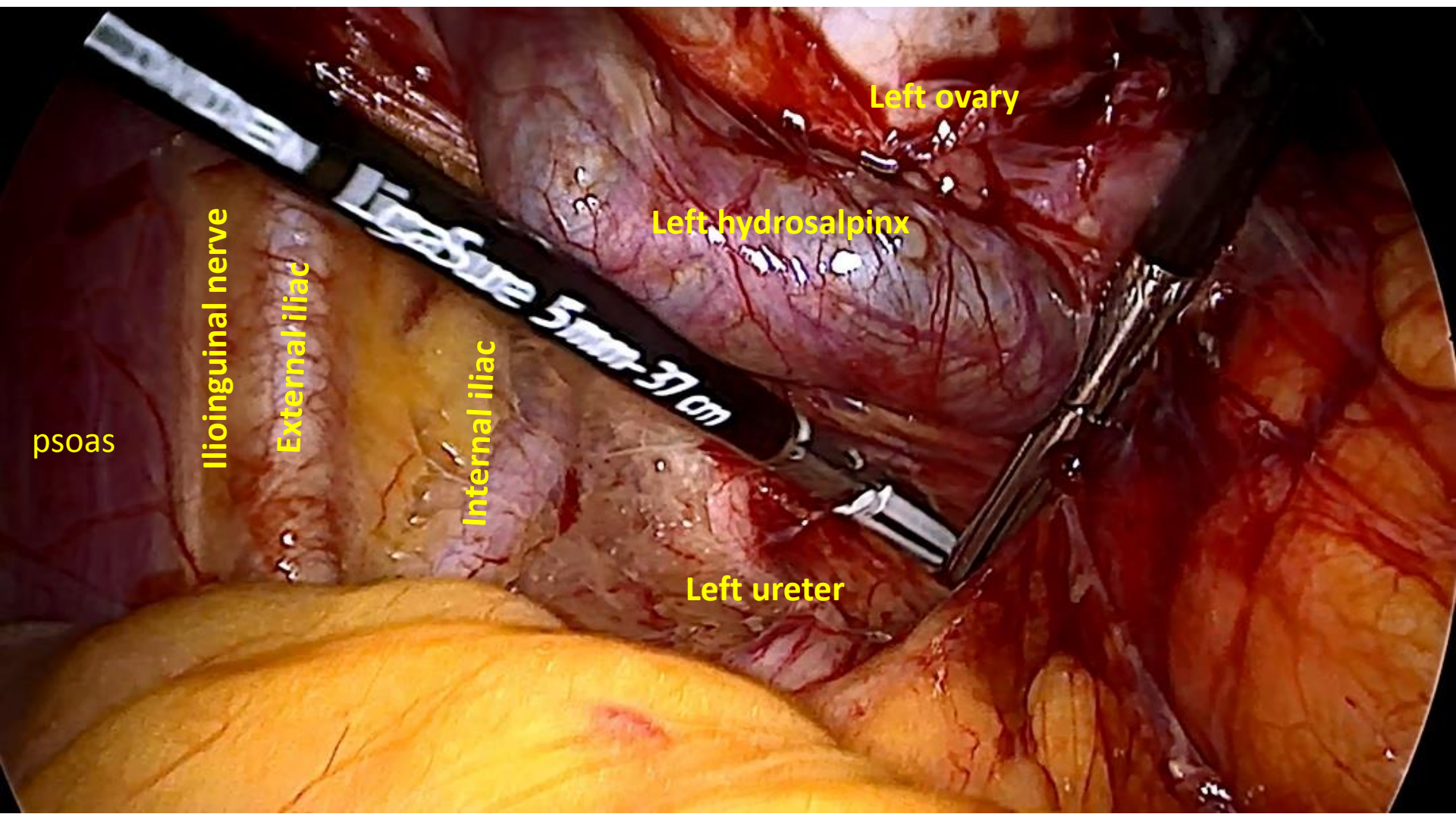

Left ovary

Left hydrosalpinx

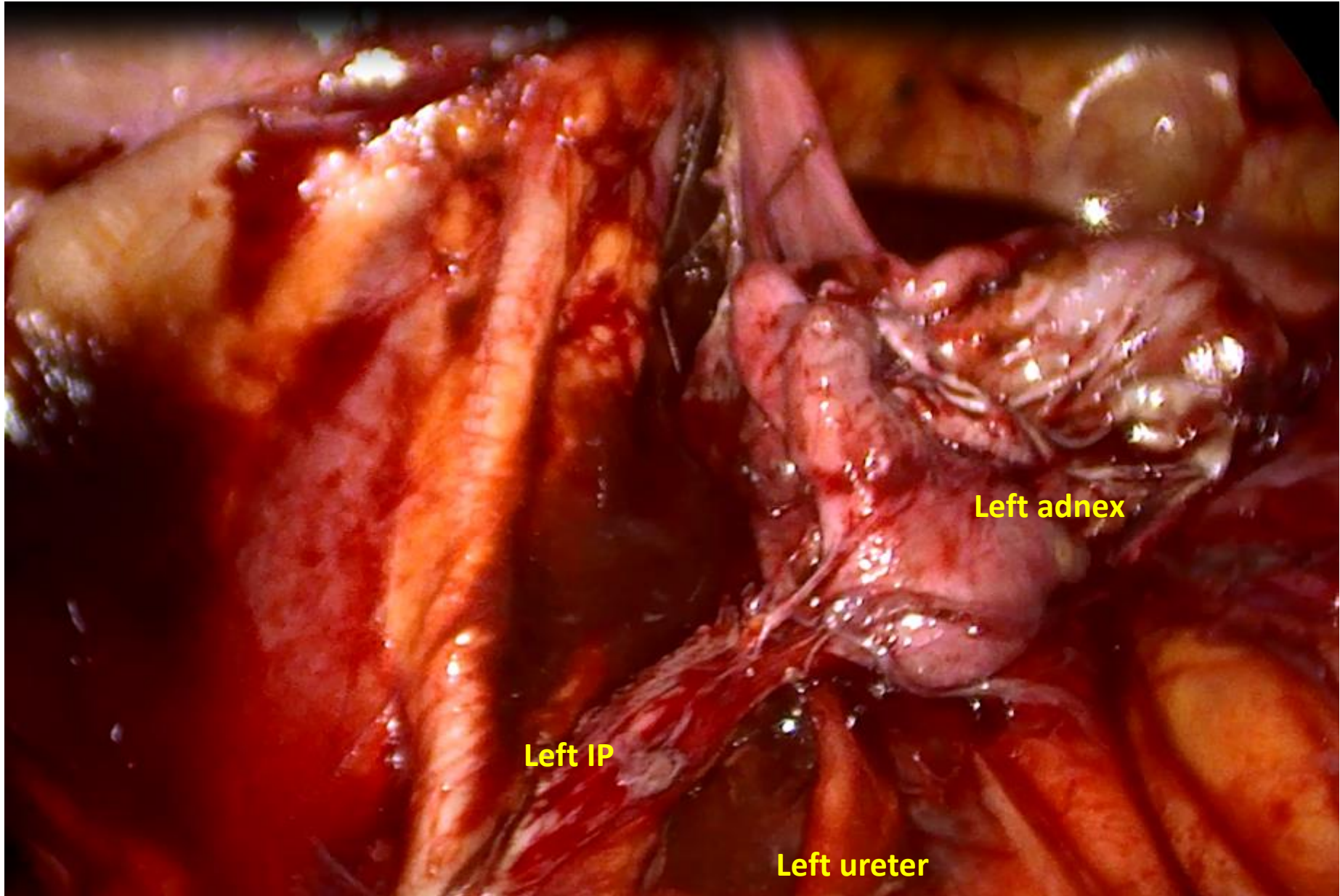
Left ureter

Internal iliac

External iliac

Ilioinguinal nerve

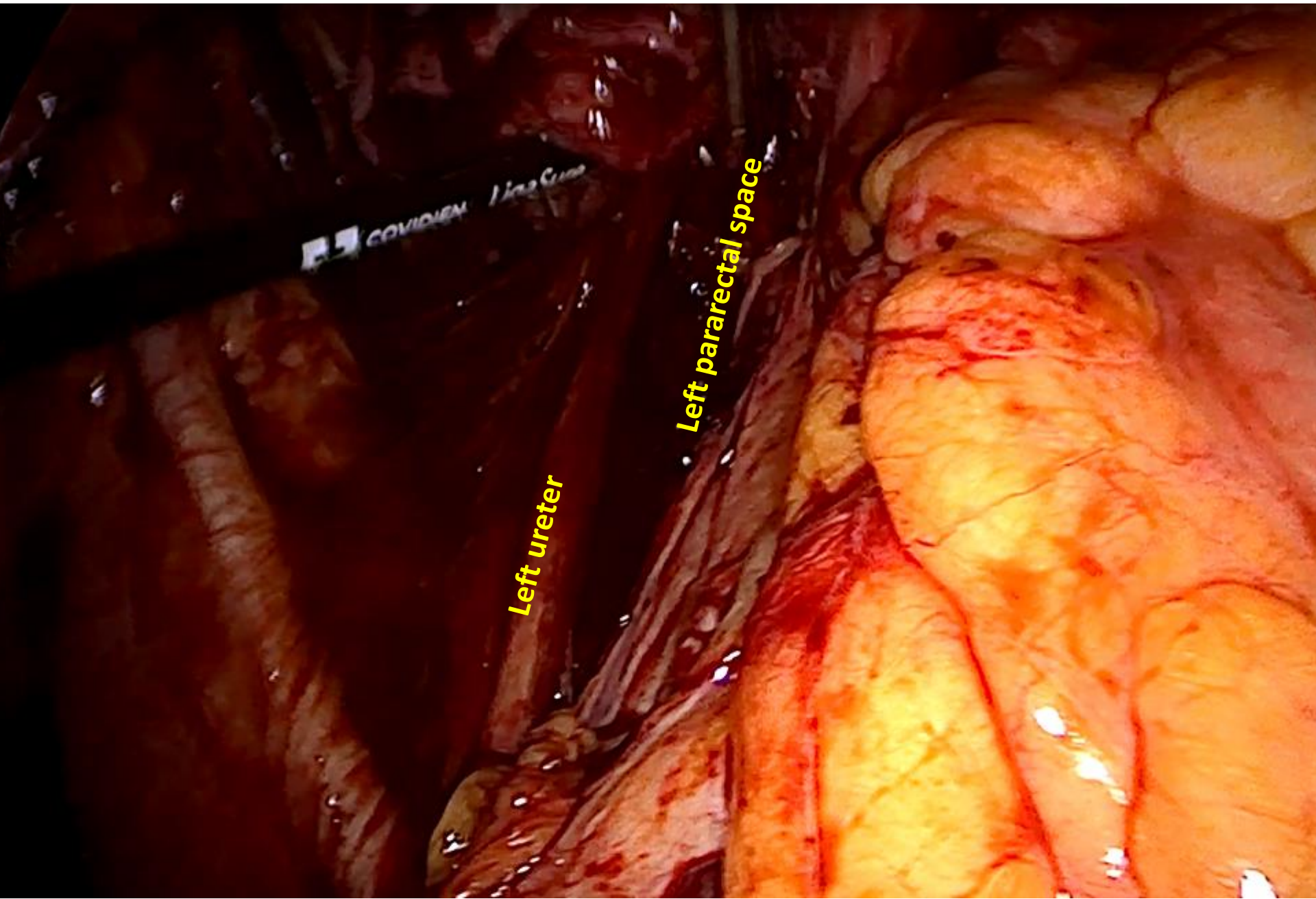
psoas



Left adnex

Left IP

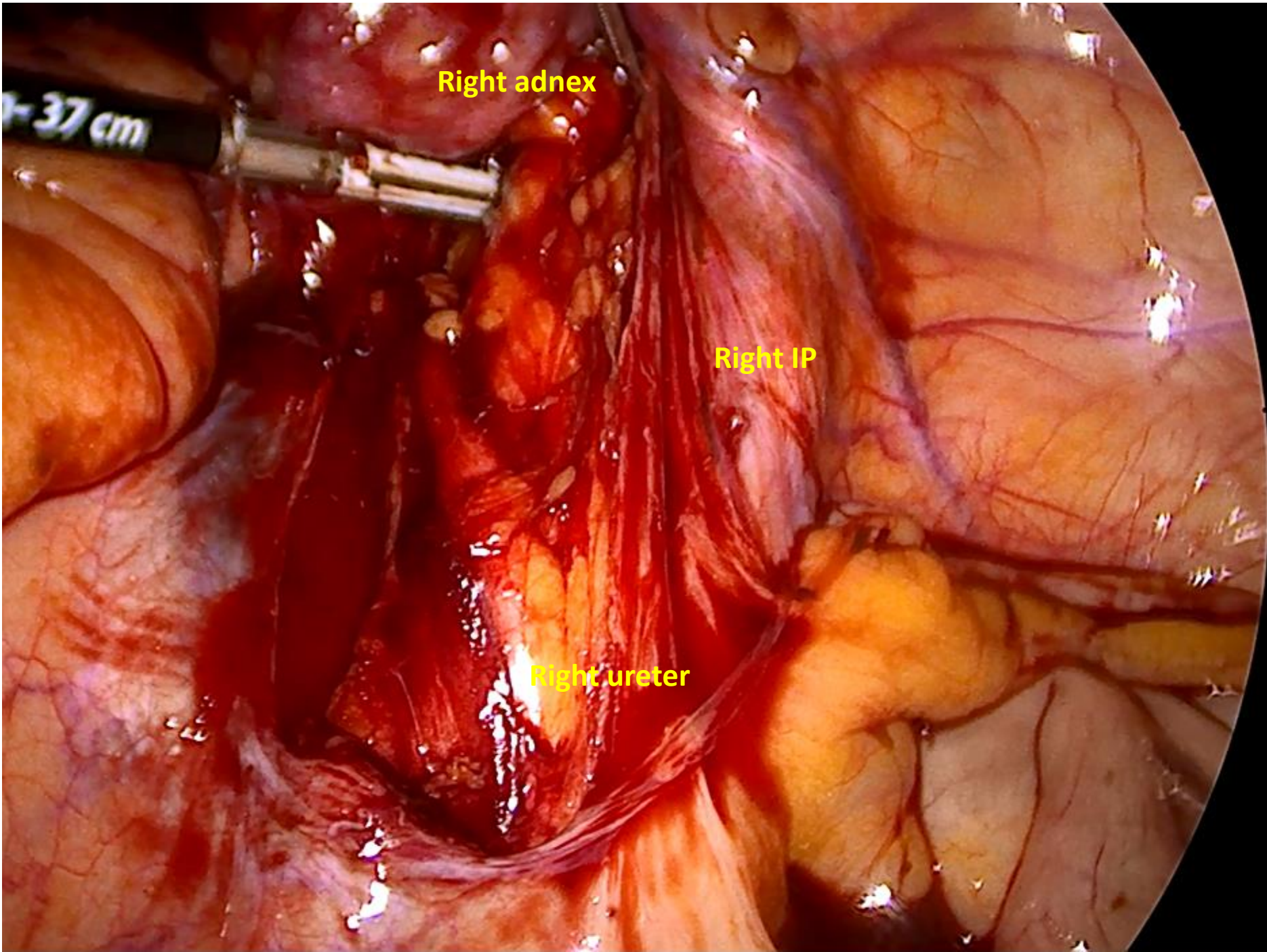
Left ureter



COVIDIEM

Left ureter

Left pararectal space

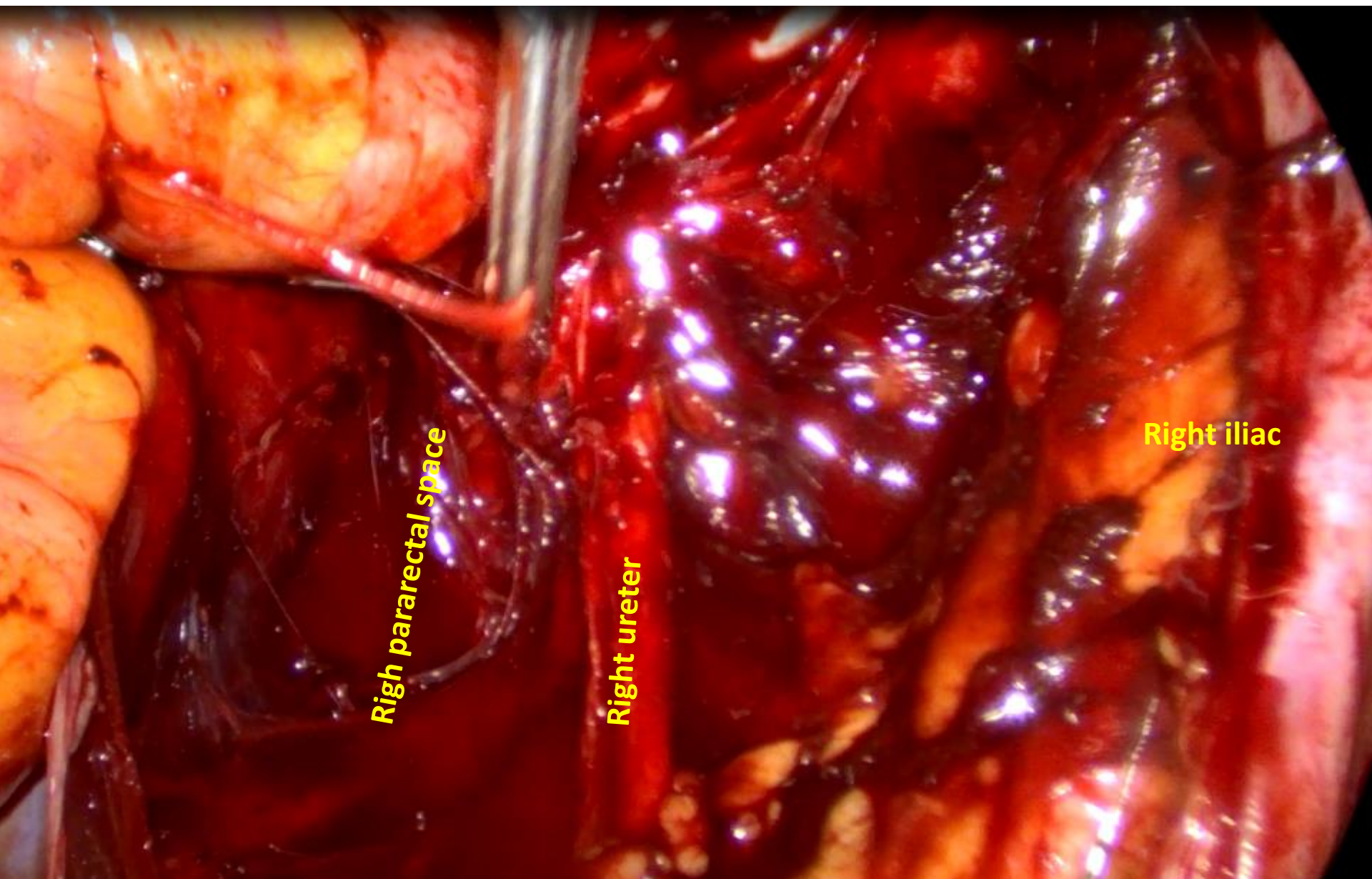


Right adnex

Right IP

Right ureter

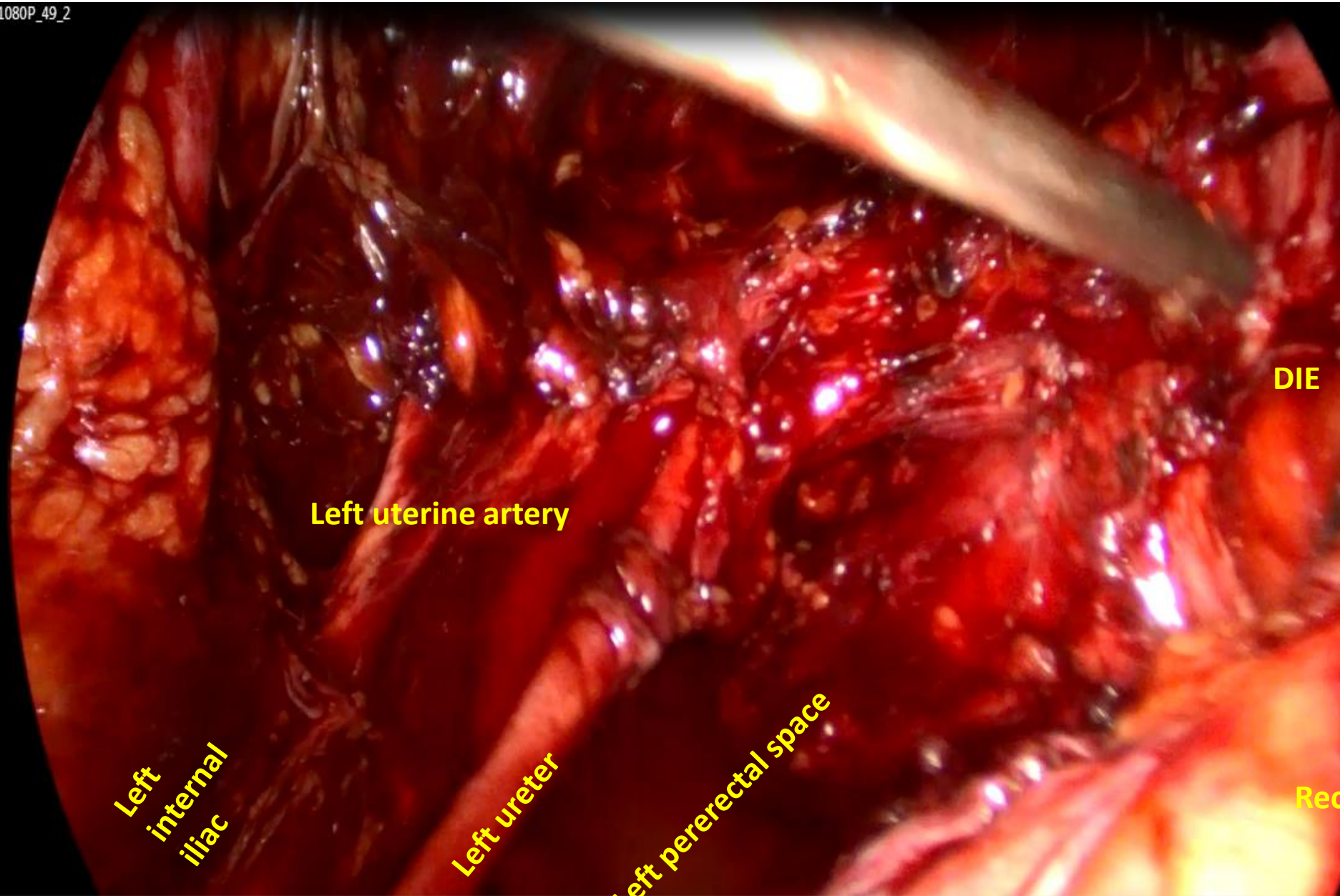
37 cm



Right pararectal space

Right ureter

Right iliac



Left uterine artery

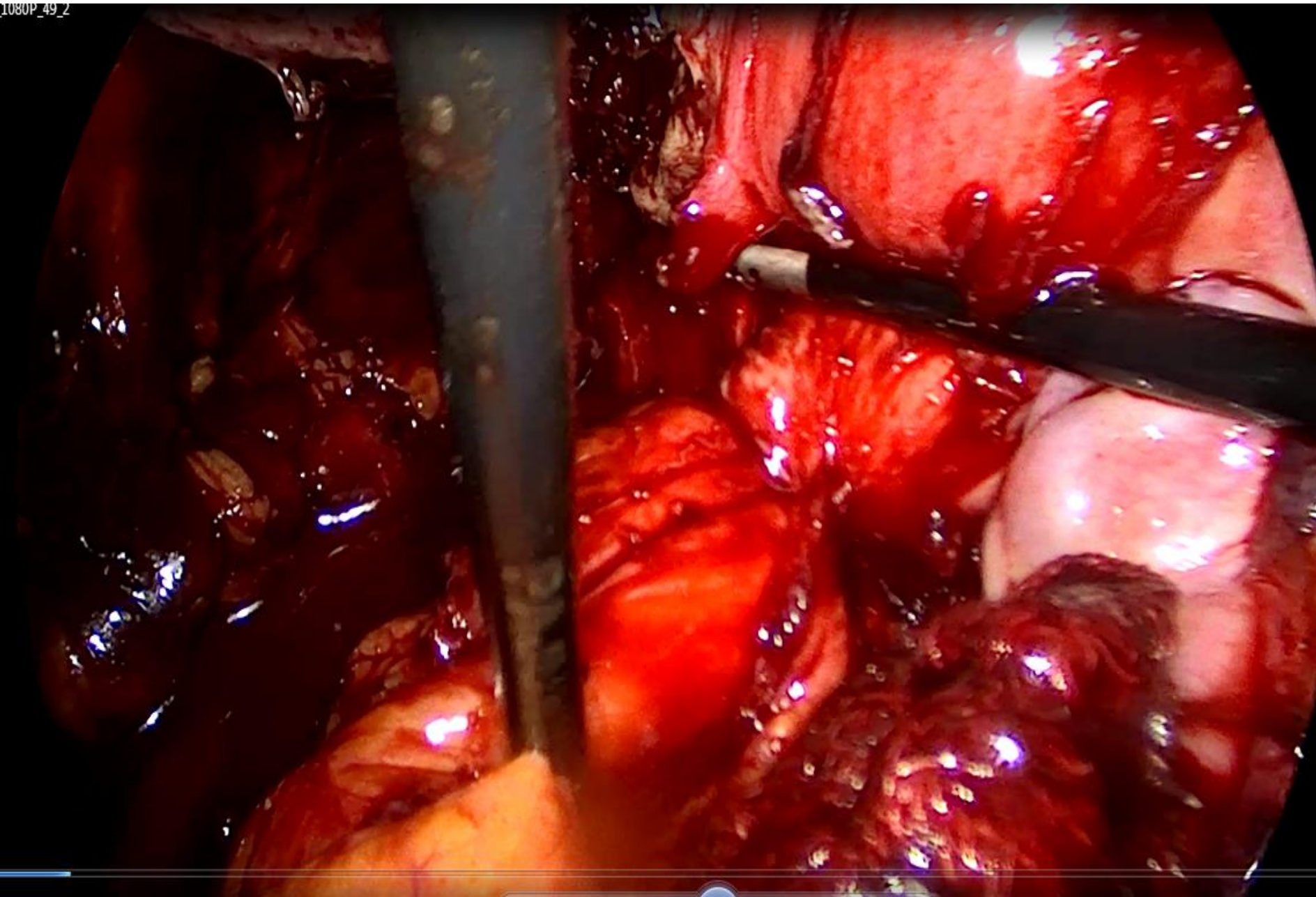
Left
internal
iliac

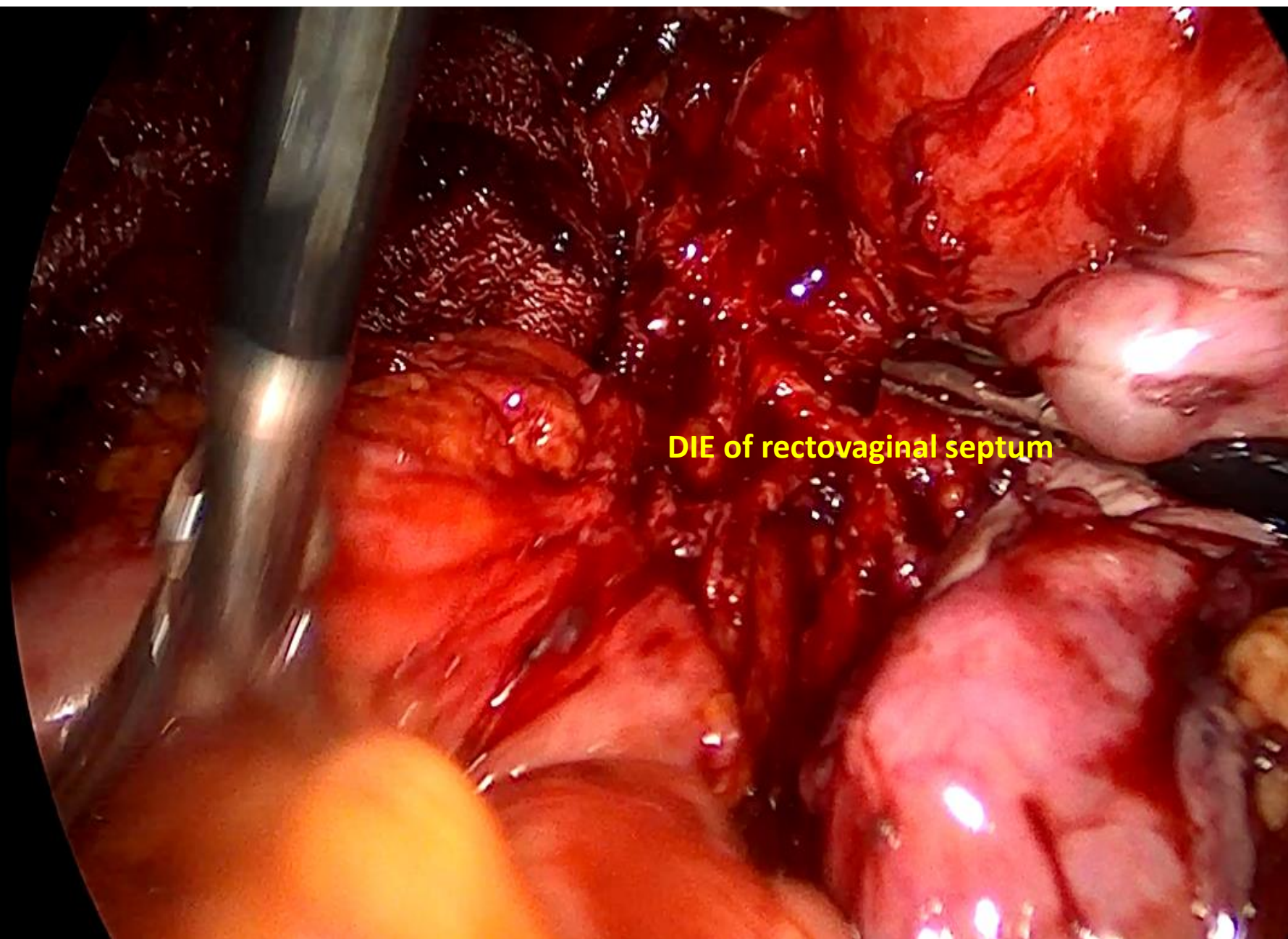
Left ureter

Left perirectal space

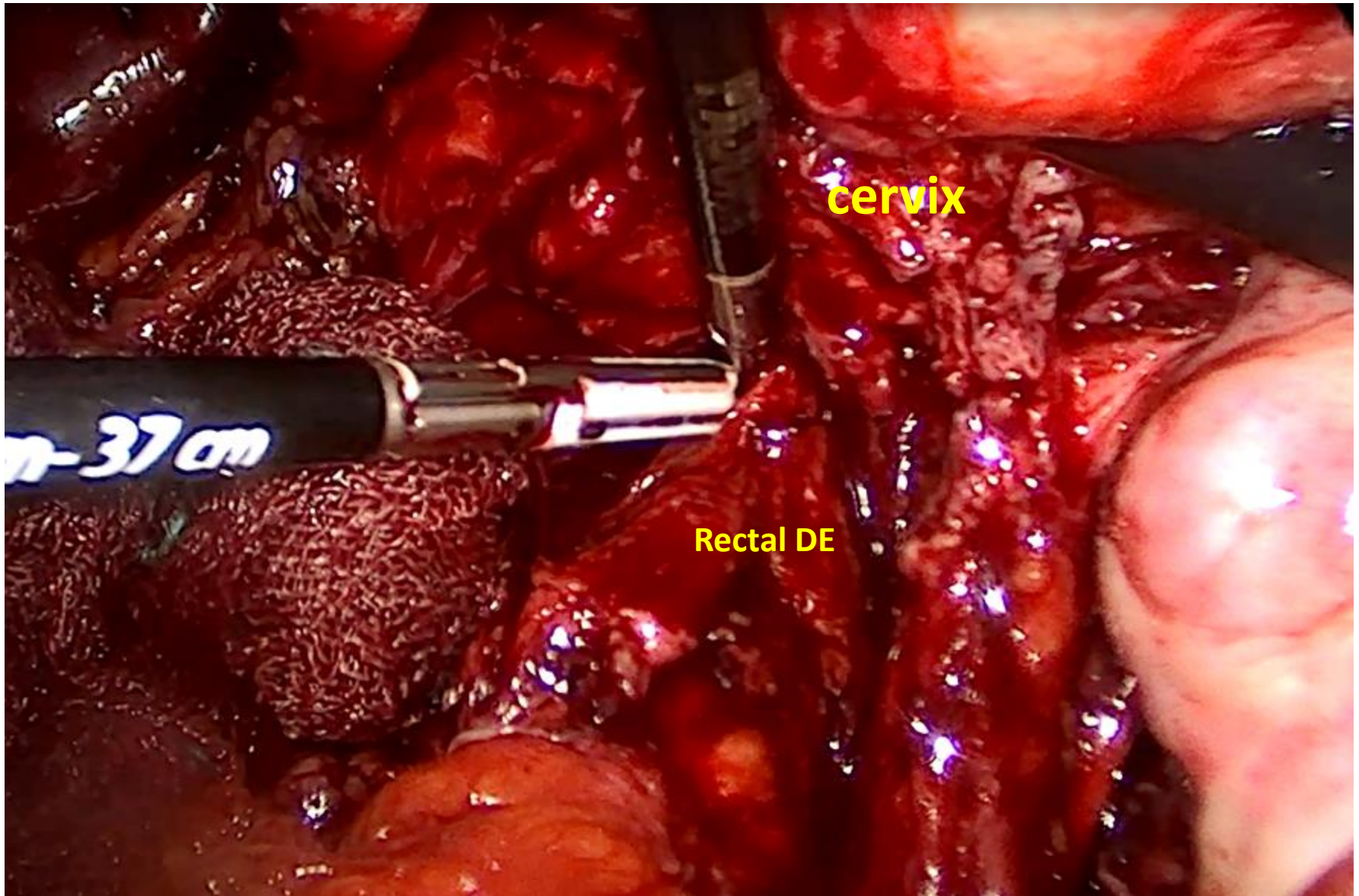
DIE

Rec





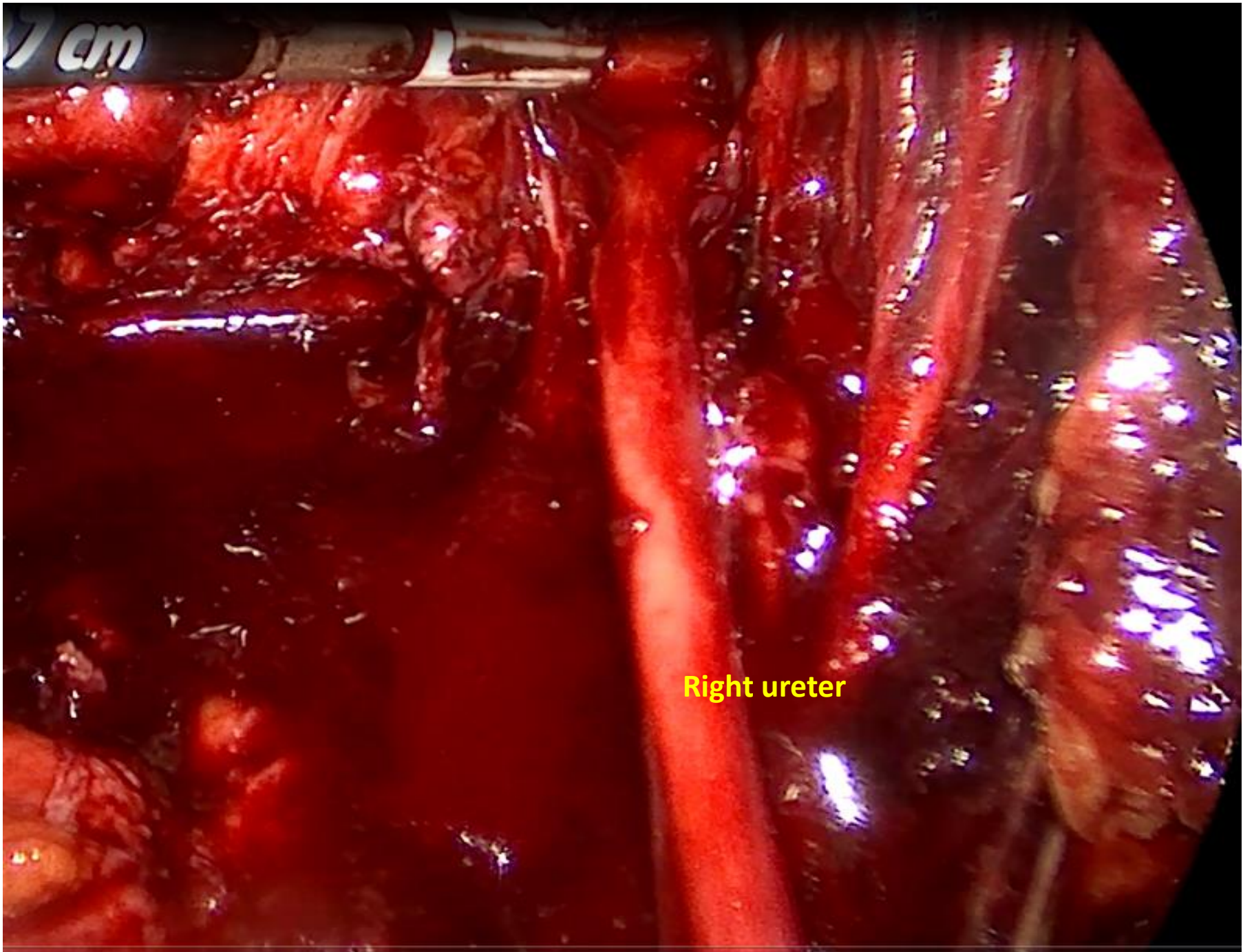
DIE of rectovaginal septum



cervix

Rectal DE

37cm



Right ureter

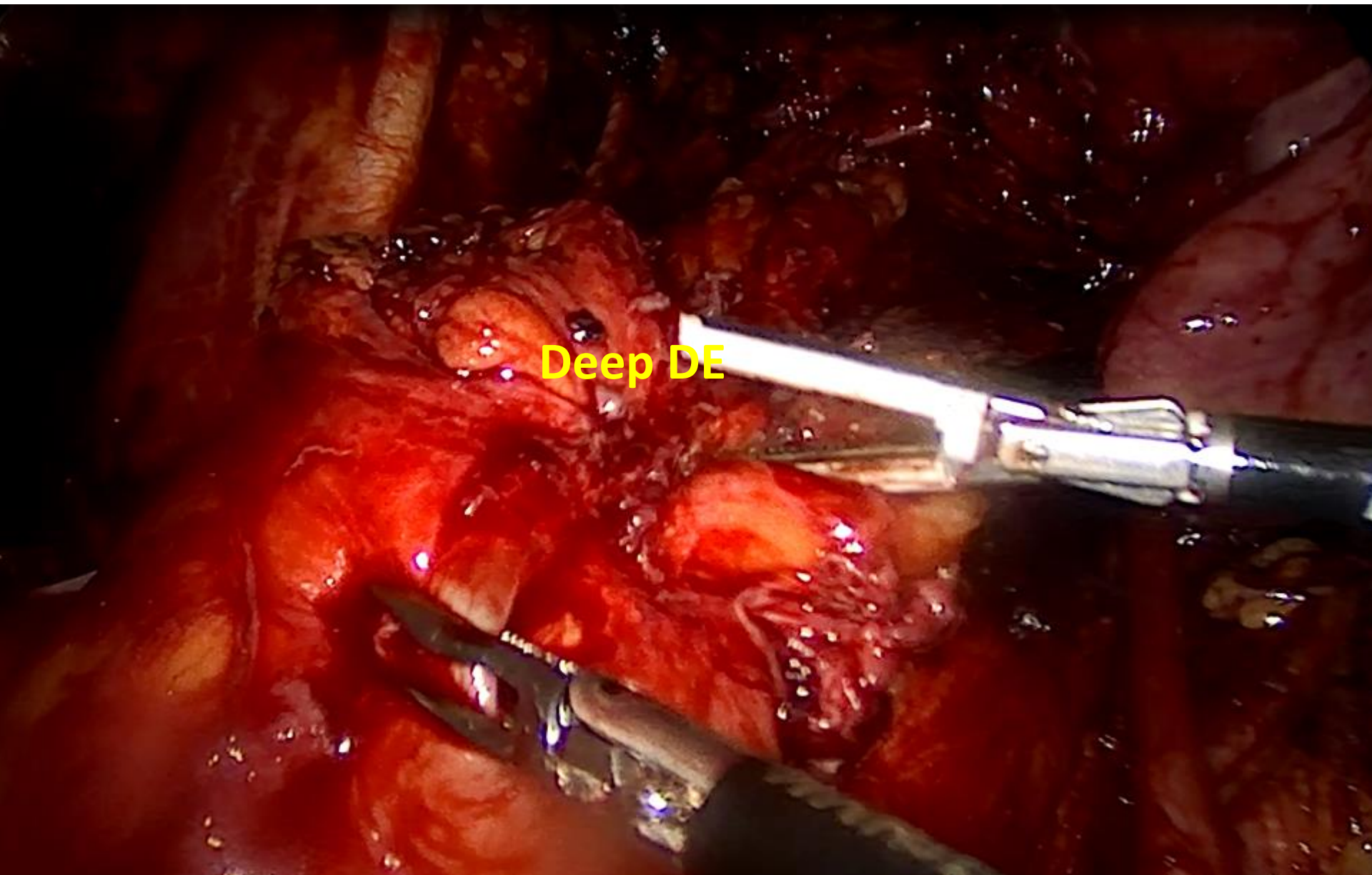


DE of rectum

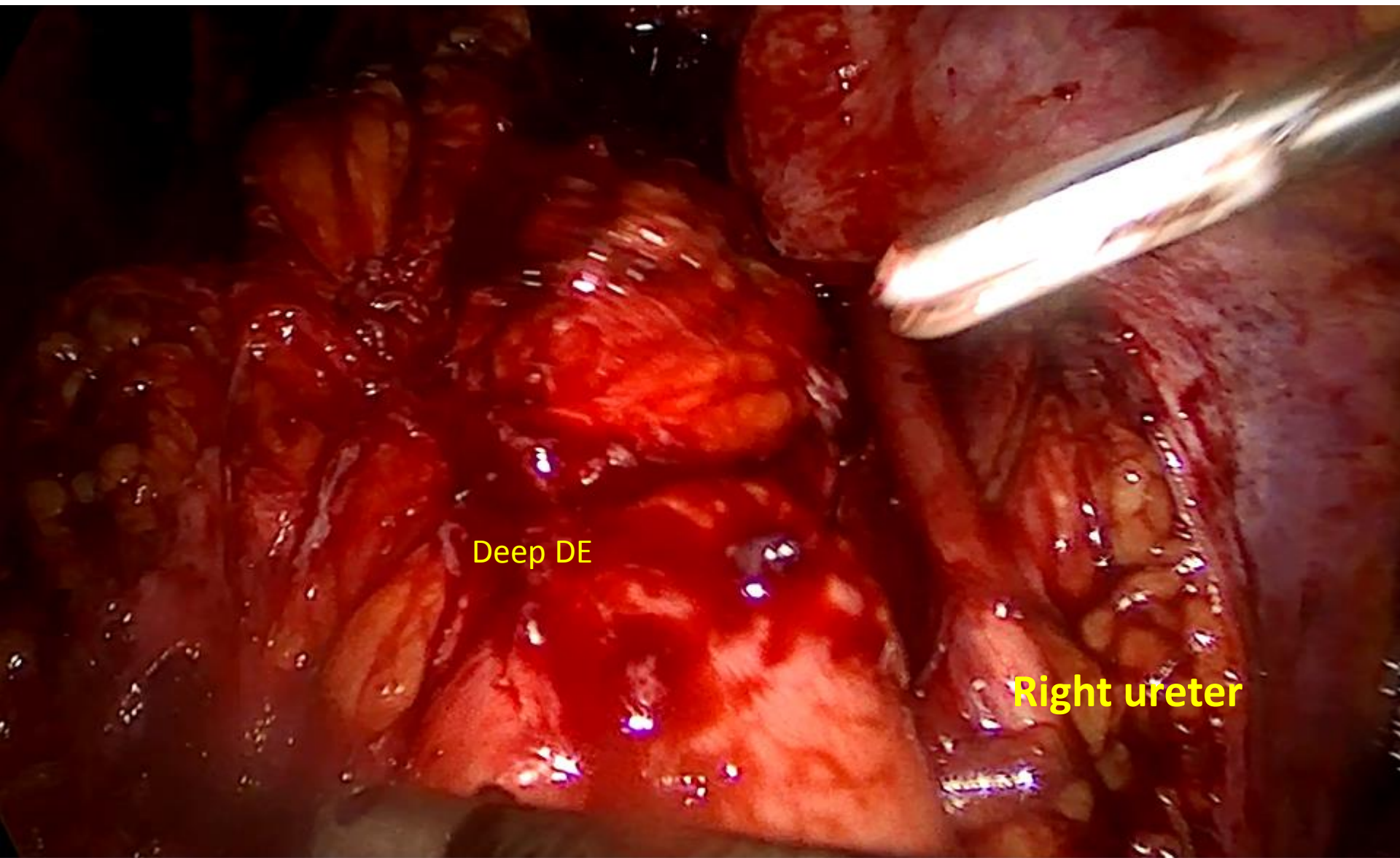
This is an intraoperative photograph showing a deep dissection of the rectum. The rectum is the central, vertical structure, appearing as a thick, reddish-brown tube. It is surrounded by various layers of tissue, including muscle and connective tissue. The dissection is performed with surgical instruments, which are visible on the right side of the frame. The overall scene is illuminated with bright surgical lights, highlighting the moist and vascular nature of the tissues.

Right ureter

Left ureter

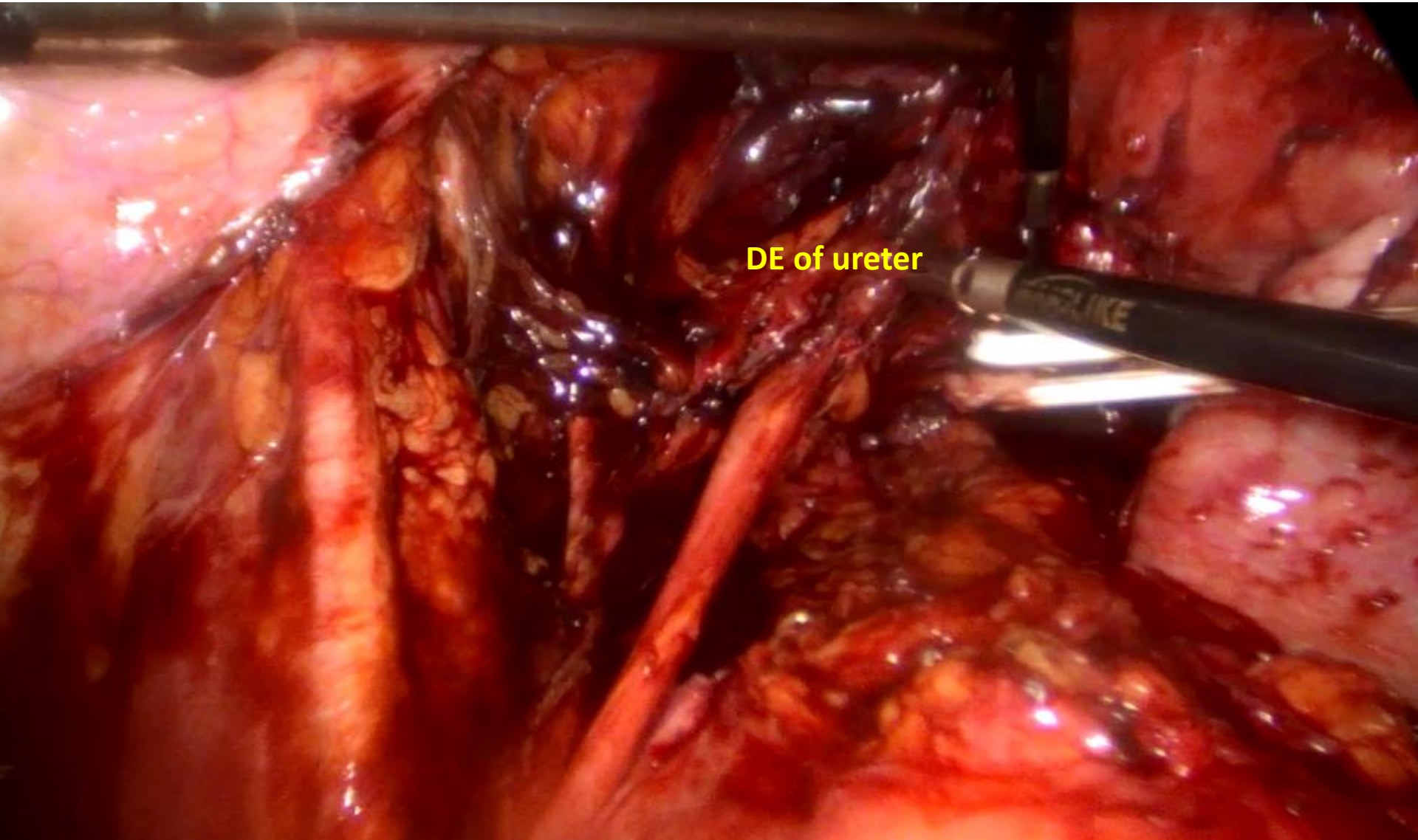


Deep DE

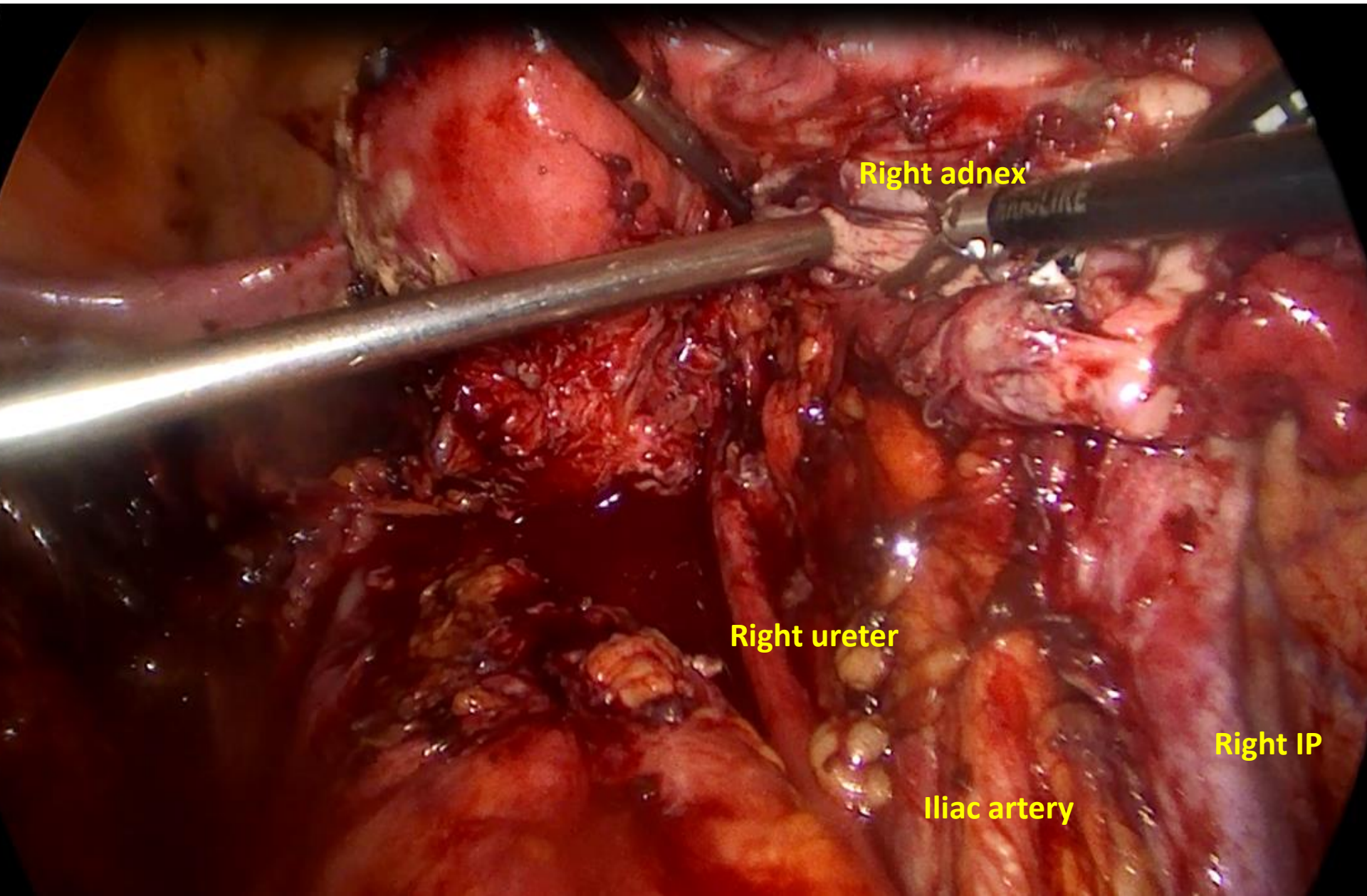


Deep DE

Right ureter



DE of ureter



Right adnex

Right ureter

Right IP

Iliac artery

