



# ***Irritable infant***

**Directed by:  
Dr.Ensiyeh Taheri**

**Assitant Proffessor of  
Isfahan Medical University**



# Irritable Infant

- **"irritable infant"** implied an infant needed to be evaluated for a serious or life-threatening condition [e.g., meningitis].
- **Crying is normal part of neurobehavioral development.**
- Parents are frequently concerned by what they consider to be excessive crying or fussiness in an infant without an obvious apparent reason.
- Most children presenting with this history will be normal or have a non-serious medical condition, but a very small proportion (**0%**) will **have a serious medical disorder.**
- The challenge to the practitioner is to identify those infants who are affected by a serious organic or life-threatening disorder.

# Irritable Infant

- To understand crying, one should pay attention to characteristics such as time, duration, frequency, intensity and variability of crying.
- Most babies cry very little during the first 2 weeks of life.
- An infant's crying gradually **increases** to an average of 117 to 133 minutes per day **until 9 weeks of age** (1.5 times/24 hr = 2/5 - 3 hr/day), then **decreases** to an average of 68 minutes per day at 1.5 to 12 weeks of age.
- Circadian changes in crying are normal and crying happens **mostly in the late afternoon and evening**. (3-11 PM)
- **Although it can be very different from one baby to another.**

**IRRITABLE INFANT**

Perform H and P ①

Diagnosis suggested by physical exam ②

YES

NO

Consolable during time of observation, looks well ⑦

YES

NO

Evidence of tooth eruption, symptoms compatible with teething ⑧

See next page

YES

NO

First episode?

YES

NO

Observe for 24 hours

History/symptoms compatible with colic:  
Normal growth and development  
History of similar episodes  
Predominantly evening occurrence  
Normal between episodes

Irritability resolved?

NO

YES

NO

YES

Teething ⑧

See next page

Normal infant ⑨  
Vaccine reaction ⑩  
Teething ⑧  
Constipation  
Overstimulation  
Viral illness

Colic ⑪  
Normal infant ⑨  
Constipation

- Tourniquet syndrome ③
- Foreign body (eye)
- OM
- M Teething
- Stomatitis
- Corneal abrasion
- Congestive heart failure
- Intussusception ④
- Other causes of acute abdomen
- Testicular torsion
- Food protein-induced enterocolitis ⑤
- Tachyarrhythmias
- Hand-foot syndrome (sickle cell disease) ⑥
- "Shaken baby syndrome"/Child abuse
- Septic arthritis/osteomyelitis
- Anal fissure (constipation)
- Encephalitis/meningitis
- Pseudotumor cerebri
- Bite (insect, spider)
- Incarcerated inguinal hernia

# Irritable Infant

- The initial evaluation of an irritable infant starts with a **careful history** and **physical examination** with the intent of ruling out potentially emergent conditions and stabilizing the patient if indicated.
- The **history** should include **questions about the characteristics of the cry** (the time of day, duration, whether it is associated with feeds) and any **changes to the infant's typical crying pattern**.
- The **History** should include the fever history and body temperature, birth history (including newborn screen results), a past medical history, nonaccidental history of trauma, review of symptoms, plus a social, familial, developmental, and feeding history, GERD, family management (calm down baby, stress managing).

•

# Irritable Infant

- In addition to questions **about recent symptoms**, medical providers should ask about any remote history of **suspicious bruising or other injury**.
- Though conditions such as **constipation, gastroenteritis, and gastroesophageal reflux** are most often benign, **poor growth or developmental delay may indicate more severe disease** or that another medical condition is causing the symptoms.

# Irritable Infant

- The physical examination should include a complete examination of all body systems with the clothing removed.
- A thorough **unclothed Physical Examination** is essential; be particularly vigilant with the otolaryngologic, ophthalmologic, cutaneous, and musculoskeletal exams. (Include palpation of long bones and careful examination of digits in the musculoskeletal exam,).
- Growth parameters should be noted. (Increasing head circumference percentile may point to increased intracranial pressure in infants with otherwise vague symptoms.)
- Careful **examination of digits is essential; fingers, toes, penis, testis** and even the **uvula** have been reported as affected sites. An area of well-demarcated **discoloration or swelling** on a distal appendage is suspicious. **Fractures , bruises, etc.**
- **Abdominal exam : Abd mass, hepatosplenomegaly, Acute abdomen sign: volvulus, Appendicitis, tumors, etc.**



# Irritable Infant

- In very young infants, **the neurologic exam** is a poor screening tool to detect subtle neuropathology, and intracranial injury may not be accompanied by external evidence of trauma.
- A history of previous neurologic symptoms, such as episodes of **unexplained seizures, apnea, altered mental status, developmental delay, or periods of extreme lethargy**, may suggest an occult head injury or other non-traumatic neuropathology.
- Consider a skeletal survey and/or head imaging in infants with this history.

# Irritable Infant

- Judgment must be used in determining whether certain subtle or **minor physical findings (abrasions, insect bites, stomatitis)** are causative.
- In cases of **severe or persistent irritability, follow-up** and possibly **additional evaluation** may be necessary.
- Patients may need to be monitored in the hospital until a diagnosis can be established.

# Irritable Infant

- ✓ An infant who can be consoled during the initial period of observation and has normal results on physical examination is not likely to have a serious illness.
- ✓ **Follow-up should be recommended within 24 hours** for any infant being evaluated for excessive fussiness or crying, even if consolable or a diagnosis seems evident. Sometimes an alternative or definitive diagnosis may become evident within 1 or 2 days of the initial presentation.
- ✓ **Parents should be counseled carefully** about worrisome signs and symptoms and reasons to follow up sooner.

# Irritable Infant

➤ **Labs or imaging based on:**

- ✓ **positive elements of the history and physical examination maybe indicated.**
- ✓ **When the history and physical examination do not suggest a diagnosis, additional laboratory or radiographic evaluation may be needed.**
- ✓ **If the infant is ill-appearing, has evidence of poor growth or developmental delay, or is persistently inconsolable beyond the initial assessment, laboratory and radiographic studies should be done**

# Irritable Infant

## ✓ Some tests to consider include:

✓ CBC

✓ ESR/CRP

✓ LP

✓ B/C

✓ VBG and complete metabolic panel

✓ amylase, and lipase

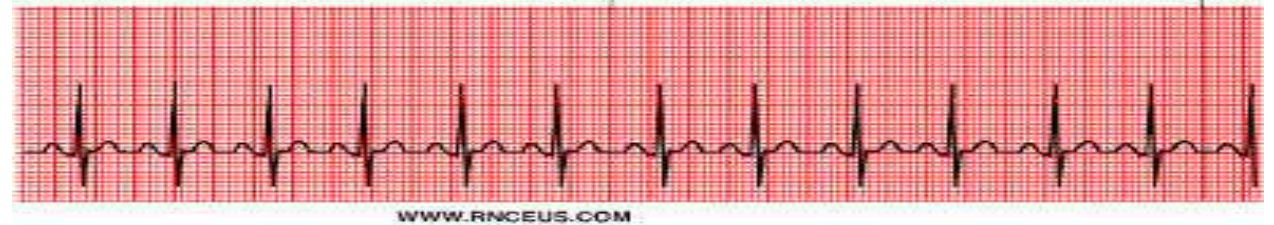✓ U/A and U/C

✓ S/E and S/C (OB+ : Food –induced allergy)

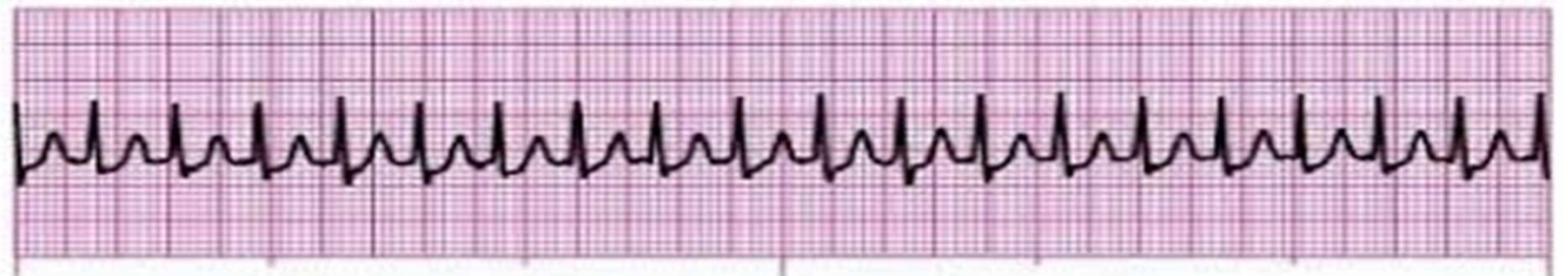
✓ ECG: arrhythmia( SVT, VT,LQT,...)

# Irritable Infant

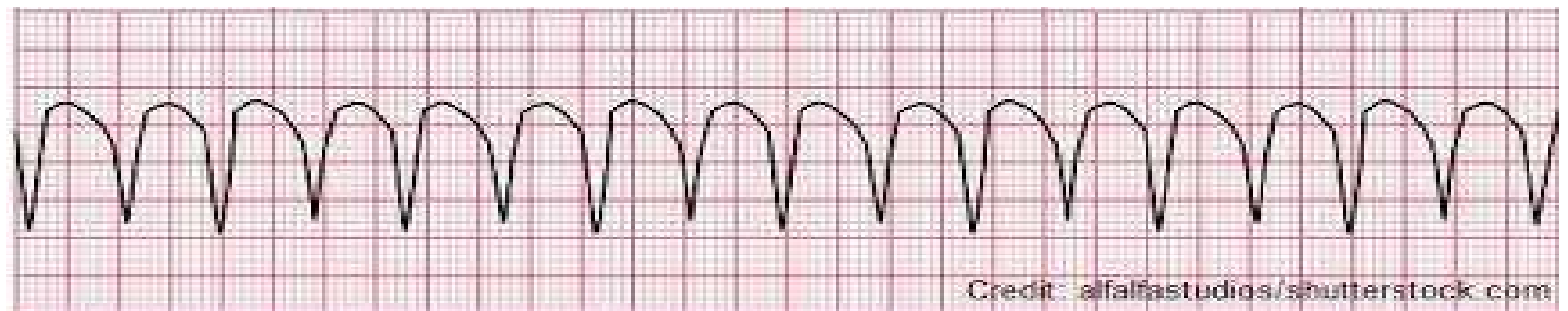
**SINUS TACHYCARDIA:**



**SVT:**



**VT:**



Tourniquet syndrome (3)

Foreign body (eye)

OM

M Teething

Stomatitis

Corneal abrasion

Congestive heart failure ★

Intussusception (4) ★

Other causes of acute abdomen ★

Testicular torsion ★

Food protein–induced enterocolitis (5)

Tachyarrhythmias ★

Hand-foot syndrome (sickle cell disease) (6)

“Shaken baby syndrome”/Child abuse ★

Septic arthritis/osteomyelitis ★

Anal fissure (constipation)

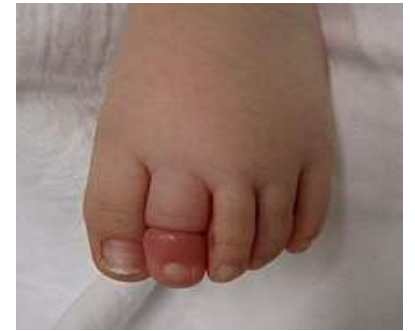Encephalitis/meningitis ★

Pseudotumor cerebri ★

Bite (insect, spider)

Incarcerated inguinal hernia ★

# Irritable Infant



## ➤ Tourniquet syndrome:

✓ **Age < 7 month** is common

✓ refers to a thin filamentous material (hair, thread) that has wrapped around an appendage and is causing **vascular compromise**.

✓ **Careful examination of digits is essential**; fingers, toes, penis, uvula, labia, tongue, umbilical cord, nipple, ear lobe, etc have been reported as affected sites.

✓ An area of **well-demarcated discoloration or swelling or hematoma** on a distal appendage is suspicious; be aware that accompanying edema and duskiness can obscure the **strangulating item**, making diagnosis difficult.

✓ The possibility of **child abuse** should always be considered.

✓ **Rapid diagnosis is necessary to minimize morbidity.**

✓ **Surgical intervention** is frequently needed, especially for cases of **penile strangulation**.



# Irritable Infant

- ✓ A urinary tract infection (**UTI**) may also present with vague **symptoms of irritability in infants**. This may be one of the few conditions in which **laboratory or imaging** leads to a diagnosis in the absence of a suggestive clinical picture.
- ✓ Some suggest that a **urinalysis and culture** should be a standard screening test in infants who present with crying.

# Irritable Infant

- **Intussusception** typically presents with:
  - ✓ A sudden onset of paroxysmal colicky episodes of pain.
  - ✓ Vomiting is common
  - ✓ Infants and toddlers are initially normal between episodes and gradually become weaker and more lethargic.
  - ✓ Most ( $\approx 60\%$ ) will pass **stool with gross blood and mucous "currant jelly"**
  - ✓ (but this may not occur for up to 1 or 2 days after symptom onset.)
- ✓ **Abdominal US followed by enema** (air, saline, water-soluble contrast) is the preferred **diagnostic and therapeutic** approach.

# Irritable Infant

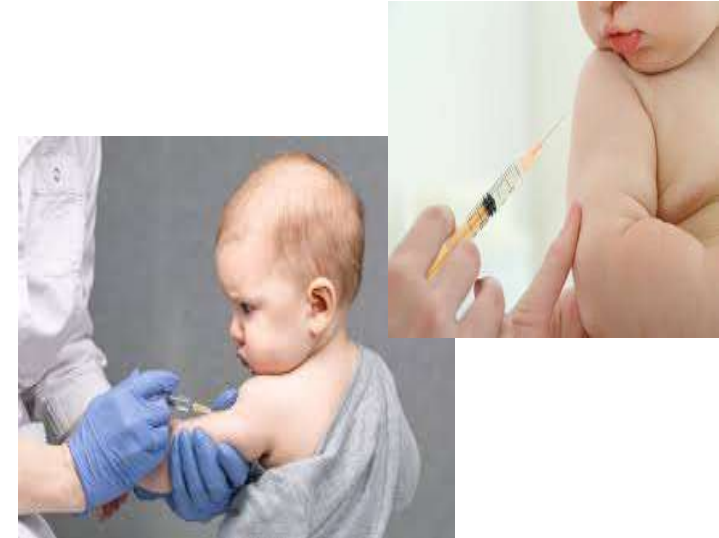## • TEETHING:

- ✓ Appropriate age (most infants **start teething around age 6 months**),
- ✓ evidence of **erupting teeth**
- ✓ **increased salivation**
- ✓ **relief with chewing on a cold object**



# Irritable Infant

## ✓ Vaccine



- **Mild fussiness** is associated with several of the standard childhood vaccines.
- **local soreness** at the injection site is generally considered the cause.
- Significant irritability related to vaccines is **unusual**; other etiologies should be considered.

# Irritable Infant

## ➤ Colic: RULES OF 3



- ✓ common definition of colic is recurrent episodes of excessive crying or fussiness at predictable times of the day, usually the evening:
- ✓ lasting more than 3 hours
- ✓ occurring on more than 3 days per week in otherwise normal infants.
- ✓ Onset is usually around 3 weeks of age
- ✓ the condition typically resolves by 3 to 4 months of age.
- ✓ It does not depend on gender , race , socioeconomic differences.
- ✓ Parental education and reassurance are necessary and important.(post partum depression/child abuse( shaken baby syndrome) , etc)

# Irritable Infant



✓ Colic:

✓ تکنیک های آرام کردن شیرخوار:

✓ قنداق کردن

✓ نگه داشتن شیرخوار به یک سمت یا روی شکم

✓ صداها یا آوازه های آرام بخش ( هیس کردن، آواز خواندن)

✓ حرکات ریتمیک آهسته یا نوسانی (سواری در ماشین، جنباندن)

✓ مکیدن گول زنک

✓ آموزش نشانه های گرسنگی

✓ اجتناب از مصرف بیش از حد کافئین

✓ عدم استفاده از الکل توسط مادر

✓ احتیاط در مورد تغذیه بیش از حد

درمان های دارویی: سایمتیکون، فنوباریتال، دیفن هیدرامین، دی سیکلومین و ... توصیه نمیشود.

برخی مطالعات نشان داده اند که پرو و پره بیوتیک ها و ماساژ کودک مفید هستند.

در مورد تاثیر طب سوزنی و گیاهی مثل چای سبز، شربت گریپ، رازیانه، محلول شکر اطلاعات ضعیف میباشد.

# Irritable Infant

## ➤ **Abstinence syndromes:**

- ✓ may occur in **infants born** to substance-abusing mothers
- ✓ **withdrawal symptoms include irritability, vomiting, diarrhea, hypertonicity, poor feeding, and sleep problems.**
- ✓ **Withdrawal usually occurs in the first week of life** but may be delayed up **to 1 to 3 weeks** if the mother was using **methadone.**

➤ **Beyond the neonatal period, breastfeeding infants may experience fussiness and irritability due to transfer of maternal drugs (decongestants, caffeine, nicotine, cocaine).**

➤ **Environmental toxins (carbon monoxide) may rarely be a cause of nonspecific infant fussiness.**

# Irritable Infant

- ✓ A head CT will diagnose intracranial hemorrhage (suspicious of child abuse) or other causes of increased ICP.
- ✓ Meningitis needs to be considered in cases of severe or inconsolable irritability; some infants will present afebrile.
- ✓ A head CT should be obtained before performing an LP in these infants to rule out increased ICP.



# Irritable Infant

- ✓ **Acidosis, hypernatremia, hypocalcemia, and hypoglycemia** are rare but serious causes of irritability in infants.
- ✓ **Inborn errors of metabolism** should be considered when there is associated vomiting, neurologic symptoms, failure to thrive, or a positive family history, including unexplained neonatal deaths.

A close-up photograph of a person's hand holding a small, white rectangular sign. The sign has a thin black border and contains the text "Thank you for your attention!". The word "attention!" is written in a larger, red, serif font, while "Thank you for your" is in a smaller, black, sans-serif font. The background is a blurred blue fabric, likely a shirt. The lighting is bright, creating some highlights on the hand and the sign.

Thank you for your  
attention!