

REVIEW ARTICLE

Edward W. Campion, M.D., *Editor*

Acute Osteomyelitis in Children

Heikki Peltola, M.D., and Markus Pääkkönen, M.D.

From Children's Hospital, University of Helsinki, and Helsinki University Central Hospital, Helsinki (H.P.); and the Division of Diseases of the Musculoskeletal System, University of Turku, and Turku University Hospital, Turku, Finland (M.P.). Address reprint requests to Dr. Pääkkönen at Turku University Hospital, Kiinamyllynkatu 4-8, P.O. Box 52, 20521 Turku, Finland, or at markus.paakkonen@helsinki.fi.

N Engl J Med 2014;370:352-60.

DOI: 10.1056/NEJMra1213956

Copyright © 2014 Massachusetts Medical Society.

BACTERIA MAY REACH BONE THROUGH DIRECT INOCULATION FROM TRAUMATIC wounds, by spreading from adjacent tissue affected by cellulitis or septic arthritis, or through hematogenous seeding. In children, an acute bone infection is most often hematogenous in origin.¹

In high-income countries, acute osteomyelitis occurs in about 8 of 100,000 children per year,² but it is considerably more common in low-income countries. Boys are affected twice as often as girls.^{2,3} Unless acute osteomyelitis is diagnosed promptly and treated appropriately,⁴ it can be a devastating or even fatal disease with a high rate of sequelae, especially in resource-poor countries where patients present with advanced disease and survivors often have complications that are serious and long-lasting.

Staphylococcus aureus is by far the most common causative agent in osteomyelitis, followed by the respiratory pathogens *Streptococcus pyogenes* and *S. pneumoniae*.⁵⁻⁹ For unknown reasons, *Haemophilus influenzae* type b is more likely to affect joints than bones. Salmonella species are a common cause of osteomyelitis in developing countries and among patients with sickle cell disease.¹⁰ Infections due to *Kingella kingae* are increasing and are most common in children younger than 4 years of age.¹¹

COMMON MANIFESTATIONS

When osteomyelitis is diagnosed, it is classified as acute if the duration of the illness has been less than 2 weeks, subacute for a duration of 2 weeks to 3 months, and chronic for a longer duration.^{1,2,12} Since any bone can be affected, patients can present with a wide variety of symptoms and signs. Multifocal osteomyelitis may occur at any age but occurs most frequently in neonates.¹

Classic clinical manifestations in children are limping or an inability to walk, fever and focal tenderness, and sometimes visible redness and swelling around a long bone, more often in a leg than in an arm (Fig. 1). Often the patient's condition has deteriorated in the days preceding clinical presentation. Calcaneal osteomyelitis may proceed insidiously and lead to a delay in seeking treatment. Spinal osteomyelitis is characteristically manifested as back pain, whereas pain on a digital rectal examination suggests sacral osteomyelitis. Acute osteomyelitis should be considered in any patient who presents with a fever of unknown origin. Acute cases occur in all age groups, with a small peak in incidence among prepubertal boys, presumably because of strenuous physical activity and microtrauma.^{1,9} Children with methicillin-resistant *S. aureus* (MRSA) osteomyelitis have a high temperature, tachycardia, and a painful limp more often than those with methicillin-susceptible *S. aureus* (MSSA).¹³

DIAGNOSIS

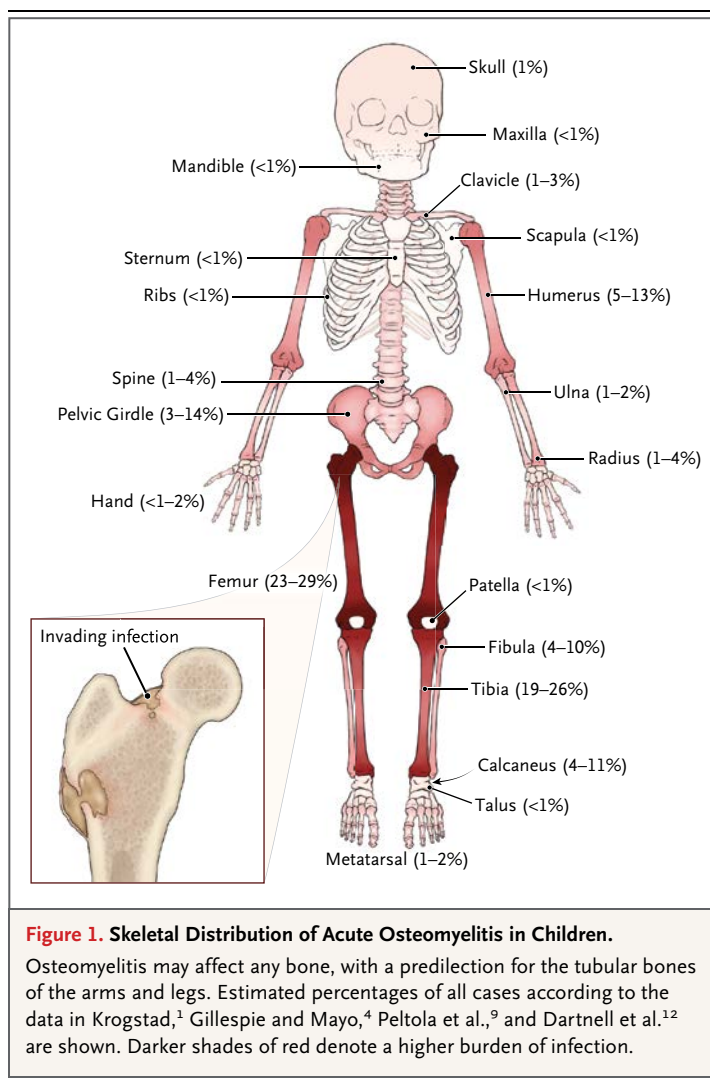
The approach to the diagnosis of osteomyelitis in children is shown in Figure 2. If physical examination suggests bone involvement, further tests are performed.

Serum C-reactive protein (CRP) and procalcitonin levels are sensitive as diagnostic tests and useful in follow-up,^{15,16} but measurements of procalcitonin are more expensive and rarely outperform those of CRP, which are easily determined from a whole-blood finger-prick sample. Results of CRP testing are available within 10 minutes. Declining levels of CRP usually suggest a favorable response to treatment,^{9,17} even if the fever continues.¹⁸ Since the erythrocyte sedimentation rate increases rapidly but decreases significantly more slowly than the CRP level, it is less useful in monitoring the course of the illness.¹⁶ As compared with other types of osteomyelitis, osteomyelitis due to MRSA causes greater elevations in the CRP level, erythrocyte sedimentation rate, and white-cell count.¹³

The “rat bite” in bone that is often seen in osteomyelitis becomes visible on plain radiography 2 to 3 weeks after the onset of symptoms and signs. A normal radiograph on admission to the hospital by no means rules out acute osteomyelitis, but it can be helpful in ruling out a fracture or detecting Ewing’s sarcoma or another type of malignant condition. In resource-poor countries, plain radiography is of great value, since no other imaging methods may be available.

Scintigraphy is sensitive and useful, especially if a long bone is affected or symptoms are not precisely localized.¹⁹ Although computed tomography (CT) is useful, it is cumbersome and entails extensive radiation exposure. Magnetic resonance imaging (MRI) is often considered the best imaging method, especially in difficult-to-diagnose cases.¹⁹ CT and MRI are costly, are not always available, and require anesthesia in young children. Ultrasonography is of minor importance, but visible fluid in an adjacent joint suggests septic arthritis.

Determining the causative organism is pivotal. Osteomyelitis can be diagnosed by means of imaging, but it is essential, whenever possible, to obtain a sample for the antibiogram that may disclose problematic agents such as MRSA.⁹ Representative samples can be obtained percutaneously or through a small incision by drilling. Blood cultures should be performed routinely, even though they identify the causative agent in only 40% of the cases.⁹ The yield of *K. kingae* can be increased with the use of special culture methods or polymerase-chain-reaction assays.¹¹ *K. kingae* should be actively searched for, since it is difficult to isolate and appears to be more



common among young children than previously thought.

MANAGEMENT

ANTIBIOTIC TREATMENT

Treatment of acute osteomyelitis is almost always instituted empirically before the causative agent and its resistance pattern are known. The most relevant antibiotics are listed in Table 1^{8,9,14,20-26}; they must have an acceptable side-effect profile when administered orally because the doses are unusually large.²⁷ Absorption and penetration into the bony structure should be satisfactory,^{21,22} and time-dependent antibiotics with a short circulating half-life are likely to require frequent dosing. Clindamycin and first-generation cephalosporins fulfill these requirements. Their efficacy as

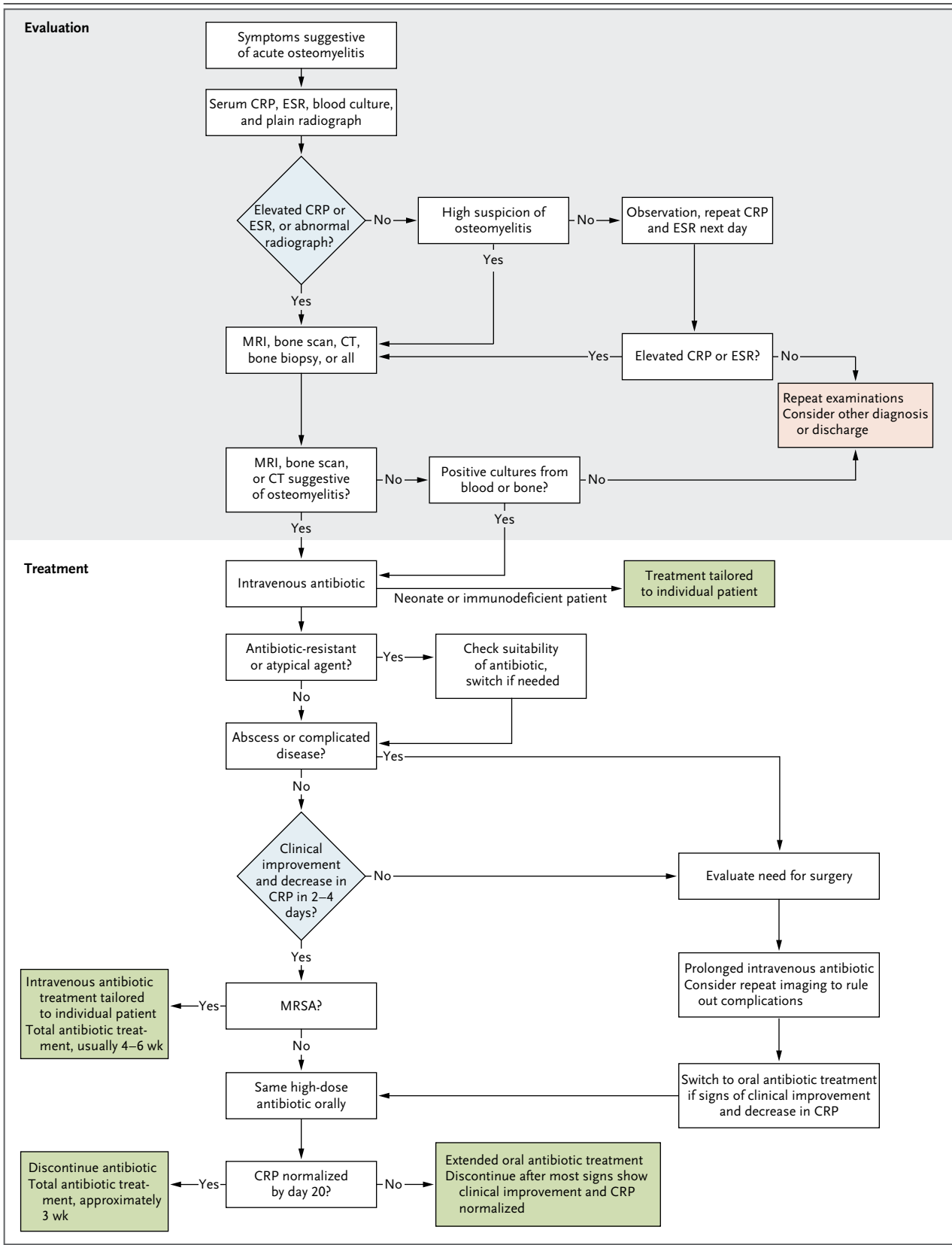


Figure 2 (facing page). Diagnosis and Treatment of a Typical Case of Acute Osteomyelitis in a Child.

The recommendations shown are from our practice in treating osteomyelitis due to methicillin-susceptible *Staphylococcus aureus* (MSSA), streptococci, or pneumococci,⁹ but recommendations vary throughout the world. Data are lacking on short-term treatment for osteomyelitis due to methicillin-resistant *S. aureus* (MRSA), and a prolonged course of treatment is still recommended.¹⁴ The cutoff value of the normal range for the C-reactive protein (CRP) level is 20 mg per liter, and the cutoff value for the erythrocyte sedimentation rate (ESR) is 20 mm per hour, regardless of the patient's age. CT denotes computed tomography, and MRI magnetic resonance imaging.

monotherapy for osteomyelitis has been documented, and large doses usually have an acceptable side-effect profile.^{20-22,27} Clindamycin very rarely causes diarrhea in children, but rash sometimes develops.²⁰ Treatment with antistaphylococcal penicillins has also been shown to be effective and safe, albeit in noncomparative or small prospective trials.^{8,28,29} Most MRSA strains remain susceptible to clindamycin,³⁰ but it (as well as vancomycin) should not be used against *K. kingae*. Beta-lactams are the drugs of choice for cases of osteomyelitis due to *K. kingae*,³¹ as well as for those due to *S. pyogenes* or *S. pneumoniae*.²⁰ The rare cases caused by *H. influenzae* type b respond to ampicillin or amoxicillin, if the strain is beta-lactamase-negative, or to a second- or third-generation cephalosporin, if the strain is beta-lactamase-positive. This agent should be considered especially in children younger than 4 years of age who have not been vaccinated against *H. influenzae* type b and who present with osteomyelitis and septic arthritis.^{9,20} For patients in unstable condition, and in areas where resistance to clindamycin is widespread, vancomycin should be chosen as a first-line agent,¹⁴ whereas the more costly linezolid should be reserved for patients who do not have a response to vancomycin.^{24,25} The adequacy of bone penetration is a concern when vancomycin is used,^{14,23} and measurement of trough levels is warranted to guarantee sufficient dosing. A small retrospective survey³² yielded encouraging results with "old-fashioned" trimethoprim-sulfamethoxazole for osteomyelitis due to MRSA, but in the absence of data from larger trials, the use of this inexpensive and in many respects favorable agent remains controversial. Osteomyelitis due to salmonella warrants a third-generation

cephalosporin, such as cefotaxime or ceftriaxone, or a fluoroquinolone.^{10,33,34} If these agents are not affordable, an older agent, chloramphenicol — which is currently not easy to obtain in developed countries — is a possibility, depending on the antibiogram profile. Its potential bone marrow effects are usually deemed to be outweighed by its benefits.³⁵

Patients with osteomyelitis may require other medications. At the attending clinician's discretion, nonsteroidal antiinflammatory drugs (NSAIDs) can be used to lower the patient's temperature and to relieve any harsh symptoms such as pain or fever.⁹ Data are lacking to support the use of glucocorticoids in acute osteomyelitis, but anticoagulants may be needed in cases that are complicated by deep-vein thrombosis, septic pulmonary emboli, or both; these conditions are characteristic of osteomyelitis due to MRSA.³⁶

SWITCH FROM INTRAVENOUS TO ORAL MEDICATION

Traditionally, a child with osteomyelitis received intravenous medication for weeks, with a switch to oral medication when recovery was almost complete.^{37,38} This was understandable, since osteomyelitis killed many children or left them crippled.^{39,40} Antimicrobial agents revolutionized treatment, although few clinicians realize that the first sulfonamide regimens in the late 1930s were mostly oral and lasted for only a few days.³⁹ Long intravenous courses were gradually adopted, and it took decades to relearn that switching to oral administration at an earlier point is not harmful.²⁷ The pressing question continues to be how soon the switch can safely be achieved.¹⁷

Three trials⁷⁻⁹ showed no change in outcomes when the intravenous phase was shorter than a week. A review from the United Kingdom concluded that short-term parenteral medication is acceptable in uncomplicated cases of osteomyelitis.¹² In our prospective series involving 131 immunocompetent children who were older than 3 months of age, to our knowledge the largest study as of this writing, intravenous treatment was administered for only 2 to 4 days, followed by oral administration.^{9,20} There were no recurrences, but no cases of MRSA were encountered. In countries such as the United States, where MRSA is a common pathogen, a more conservative approach is probably well founded while we await sufficiently powered prospective clinical trials to assess this important issue.

Table 1. Antibiotic Treatment for Acute Osteomyelitis in Children.*

Antibiotic	Dose mg/kg/day	Maximal Daily Dose†	Bone Penetration‡ %	Reference
Empirical treatment				
First-generation cephalosporin, if prevalence of MSSA in community >90%§	≥150 administered in 4 equal doses¶	2–4 g	6–7	Dose: Peltola et al., ⁹ Peltola et al. ²⁰ ; extent of bone penetration: Tetzlaff et al. ²¹
Antistaphylococcal penicillin (cloxacillin, flucloxacillin, dicloxacillin, nafcillin, or oxacillin), if prevalence of MSSA in community >90%	≤200 administered in 4 equal doses	8–12 g	15–17	Dose: Jagodzinski et al. ⁸ ; extent of bone penetration: Tetzlaff et al. ²¹
Clindamycin, if prevalence of MRSA in community ≥10% and prevalence of clindamycin-resistant <i>S. aureus</i> <10%	≥40 administered in 4 equal doses	Approximately 3 g	65–78	Prevalence of microorganisms: Liu et al. ¹⁴ ; dose: Peltola et al., ⁹ Liu et al., ¹⁴ Peltola et al. ²⁰ ; extent of bone penetration: Feigin et al. ²²
Vancomycin, if prevalence of MRSA in community ≥10% and prevalence of clindamycin-resistant <i>S. aureus</i> ≥10%	≤40 administered in 4 equal doses	Dosing adjusted according to trough level, with a target of 15 to 20 µg per milliliter	5–67	Prevalence of microorganisms: Liu et al. ¹⁴ ; dose: Liu et al. ¹⁴ ; extent of bone penetration: Landersdorfer et al. ²³
Linezolid, if no response to vancomycin	30 administered in 3 equal doses	1.2 g for no more than 28 days	40–51	Dose: Kaplan et al., ²⁴ Chen et al. ²⁵ ; extent of bone penetration: Landersdorfer et al. ²³
Alternatives for specific agents				
Ampicillin or amoxicillin for group A beta-hemolytic streptococcus, <i>Haemophilus influenzae</i> type b (beta-lactamase-negative strains), and <i>S. pneumoniae</i>	150–200 administered in 4 equal doses	Approximately 8–12 g	3–31	Dose: Peltola et al. ⁹ ; extent of bone penetration: Landersdorfer et al. ²³
Chloramphenicol, if safer agents not available or affordable	75 administered in 3 equal doses¶	2–4 g	39	Dose: Krogstad ¹ ; extent of bone penetration: Summersgill et al. ²⁶

* When relevant, the same dose may be used parenterally and orally. MRSA denotes methicillin-resistant *Staphylococcus aureus*, and MSSA methicillin-susceptible *S. aureus*.

† The maximal daily dose is not always well defined, but the maximal adult dose should not be exceeded.

‡ Bone penetration is the ratio of the bone concentration to the serum concentration.

§ Data on antistaphylococcal penicillins, first-generation cephalosporins, and clindamycin^{21,22} are from in vivo studies involving children; the remaining data were derived from studies involving adults or from experimental models.

¶ Cephalothin and cefazolin are administered intravenously, cephalexin and cefadroxil are administered orally, and cephradine is administered by either route. If no parenteral first-generation agent is available, cefuroxime can be used for parenteral administration.

|| Chloramphenicol at a dose of 100 mg per kilogram of body weight per day in four equal doses is generally used in bacterial meningitis.

DURATION OF TREATMENT AND DIFFICULT-TO-TREAT PATHOGENS

In one study in 1960, two factors — a delay in initiating treatment and antibiotic courses of less than 3 weeks' duration — were deemed to be risk factors for relapse,⁴¹ although other retrospective studies showed no advantage with courses that were prolonged for more than approximately 21 days.^{4,5} In a British study, cloxacillin was administered for “an arbitrary period of five weeks,”²⁸ and this approach became almost dogma for four decades.^{6,14,42} In our prospective randomized trial, a 20-day regimen of high-dose

clindamycin or a first-generation cephalosporin (doses are listed in Table 1) performed as well as a 30-day regimen for osteomyelitis caused by MSSA, streptococci, or pneumococci.^{9,20} Shortened regimens of primarily oral antibiotics appear to simplify the entire treatment process in terms of the required hospital stay, the antibiotics used, and the risk of adverse events; in addition, the risk of bacterial resistance is reduced. Furthermore, with very few exceptions, oral antibiotics are considerably cheaper than parenteral formulations, and oral administration on an outpatient basis also reduces the cost of treatment.

Current clinical-practice guidelines of the Infectious Diseases Society of America recommend individualized therapy and typically a minimum of 4 to 6 weeks of medication for children with acute osteomyelitis due to MRSA.¹⁴ Since data on short-term treatment for cases due to MRSA or the virulent Panton–Valentine leukocidin gene-expressing *S. aureus* are lacking,⁴³ this recommendation is justified. It may also apply to patients who present with advanced disease and those in areas where osteomyelitis due to salmonella is common. Pathologic fractures are associated with a type of MRSA that is characterized by a single pulsed-field pattern (strain USA300-0114),⁴⁴ but even a fracture does not necessarily warrant surgical intervention. As compared with MSSA, MRSA is more frequently associated with deep-vein thrombosis, septic pulmonary emboli, or both.³⁶ Whereas resistance to methicillin is associated with an increased risk of complications in staphylococcal disease, pneumococcal resistance to penicillin has not been associated with an increased risk of complications in pneumococcal osteoarticular disease.⁴⁵

There are some other caveats in relation to shorter treatments as well. Although data are lacking on the use of shorter treatments in neonates, immunocompromised or malnourished patients, and patients with sickle cell disease, these patients are likely to need a longer course of medication.⁴⁶ When acute osteomyelitis is complicated by septic arthritis, the disease is chronic, and the CRP level normalizes slowly, a longer course probably also makes sense. Figure 2 summarizes the treatment of acute osteomyelitis.

ROLE OF SURGERY

Since data are lacking from randomized trials of surgery for osteomyelitis in children, questions about the timing and extent of surgery and the overall need for surgical intervention other than biopsy remain unanswered. Conservative treatment is effective in up to 90% of cases of acute osteomyelitis if it is diagnosed early in the course of the illness.^{38,42} In a series of 68 patients who underwent aggressive primary surgery, 17% of the patients had chronic osteomyelitis after the procedure.⁴⁷ An important observation made in the pre-antibiotic era was that immediate surgery for osteomyelitis was associated with increased mortality, whereas sequelae were rather rare, and vice versa: if surgery was delayed by a week or so,

mortality decreased and there were more sequelae.⁴⁰ Since it is conceivable that extensive intervention in the initial, critical moments of treatment produces more harm than benefit, perhaps only trepanation or drainage should be performed. Once the patient's condition is stable, or if there is no response to medication within days, an intervention such as draining an abscess might speed up the healing process.^{9,42,48} Data from prospective trials are required to explore these issues further. Aggressive débridement has been suggested in difficult-to-treat cases of MRSA, but again, data from relevant trials are lacking.⁴⁹ Intraosseous abscesses in cases of subacute or chronic osteomyelitis (Brodie's abscesses) are often thought to require surgery.⁵⁰

CASE REPORT

Fever, focal redness (Fig. 3A), and pain in the left biceps region developed in an 8-year-old boy who had not had prior trauma. A radiograph obtained 2 days later was normal (July 10 in Fig. 3B), the leukocyte count was 10,000 per cubic millimeter, and the serum CRP level was clearly increased, at 106 mg per liter (normal level, <20).¹⁶ The child was hospitalized. Three days later, the leukocyte count was only 4100 per cubic millimeter, whereas the CRP level had increased to 384 mg per liter, and the erythrocyte sedimentation rate was 66 mm per hour (normal level, <20).¹⁶ MRI showed massive edema around the proximal humerus. A specimen for bacteriology was drilled from the bone, and a blood culture was obtained; acute osteomyelitis was diagnosed. Intravenous clindamycin was administered, with cefuroxime for concomitant pneumonia. The child's condition deteriorated for 2 days, and then he began to recover. MSSA grew from the bone and blood cultures. Treatment with clindamycin was switched to oral administration on day 2, and cefuroxime was discontinued on day 7. The boy was discharged on day 11, when the CRP level was 113 mg per liter and the erythrocyte sedimentation rate was 117 mm per hour. On day 20, recovery was well advanced, and because the CRP level had normalized, clindamycin was discontinued. The patient was afebrile, but the erythrocyte sedimentation rate was still elevated, at 100 mm per hour.

At follow-up 1 month later, the boy's parents reported that he was doing well, except that climbing a ladder caused pain in the upper arm. A plain radiograph (Sept. 2 in Fig. 3B) revealed a patho-

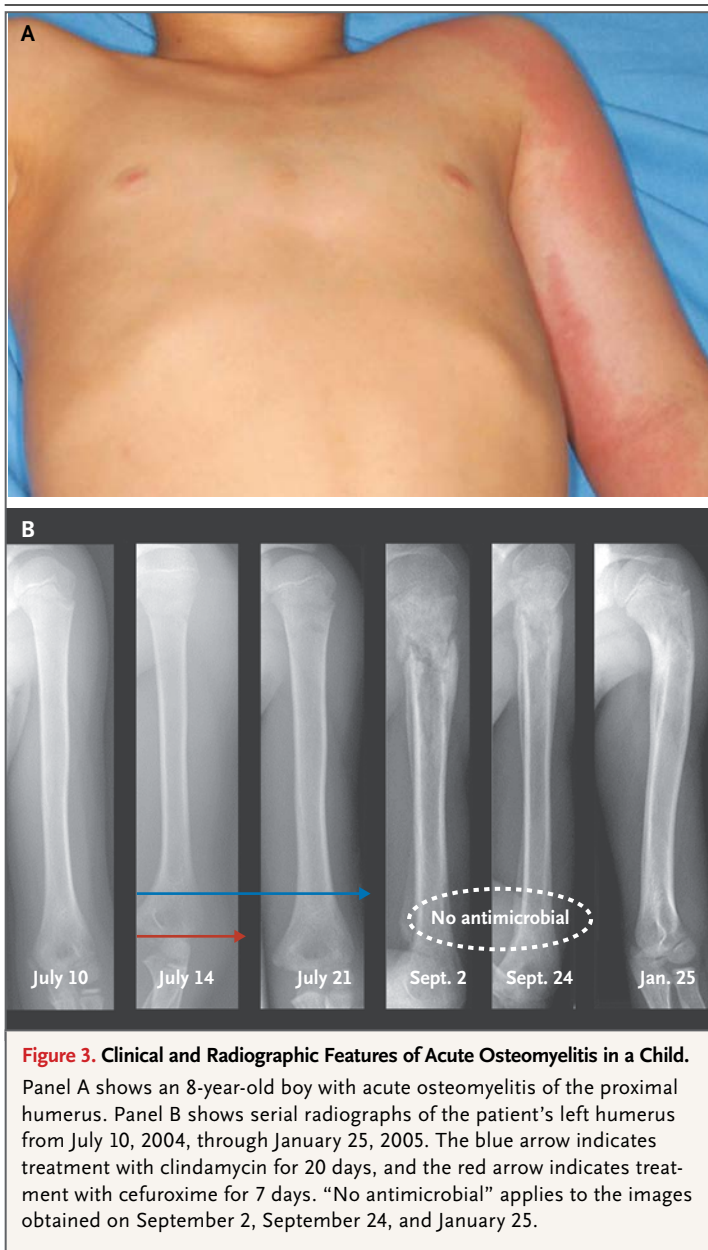


Figure 3. Clinical and Radiographic Features of Acute Osteomyelitis in a Child.

Panel A shows an 8-year-old boy with acute osteomyelitis of the proximal humerus. Panel B shows serial radiographs of the patient's left humerus from July 10, 2004, through January 25, 2005. The blue arrow indicates treatment with clindamycin for 20 days, and the red arrow indicates treatment with cefuroxime for 7 days. "No antimicrobial" applies to the images obtained on September 2, September 24, and January 25.

logic fracture in addition to callus formation and other signs of healing. Since the bone was stable and the CRP level and erythrocyte sedimentation rate had normalized, antimicrobial treatment was not reinstated. The recovery was uneventful. Two years later, the boy was well and the fracture had healed, with no bone or joint infections. Seven years after the disease, the patient remained asymptomatic. Figure 3B shows the radiographic findings during and after this potentially life-threatening, septicemic *S. aureus* infection.

Clinicians tend to prolong or reinstitute antibiotic therapy and often recommend surgery in

patients with a pathologic fracture.^{44,47} One should, however, distinguish active infection, in which bacteria are still alive, from inflammation, a much lengthier process. Spontaneous healing was well under way 1 month after discharge, and no fistula had developed. The normalized CRP level and erythrocyte sedimentation rate virtually ruled out ongoing active infection.¹⁶ Even fever, which is a less specific warning sign than CRP in osteoarticular infections, was absent, and the child's general condition was good.¹⁸ Furthermore, a radiograph showed good callus formation — another favorable sign. Ultimately, we saw no indication for reinstating antibiotics; pain relief and watchful waiting sufficed at this stage of recovery.

RESPONSE TO TREATMENT AND OUTCOMES

Unlike cases of acute osteomyelitis in developing countries, those in developed countries are rarely fatal. In a national epidemiologic study in France involving more than 1000 children with osteomyelitis, only 1 child died.³ Hospital admission that is delayed for 5 days or more is a probable risk factor for slow recovery and a poor outcome.^{9,41} Usually, active infection is eliminated rather easily with well-targeted antibiotics, whereas the inflammatory process, which ultimately heals the bone, may persist for months. Antibiotics play no role at this stage, but NSAIDs may be used to mitigate symptoms. Follow-up for a year or more is justified, since sequelae such as growth disturbance may emerge slowly. Our own study included 131 children with culture-confirmed acute osteomyelitis; mild sequelae developed in only 2 children.⁹ Less favorable outcomes may occur, since sequelae rates vary regionally and depend on many factors such as antibiotic resistance, economic conditions, and access to health care.^{6-9,35,36,43,44} Overall, however, the past few years have seen great strides in simplifying the treatment of acute osteomyelitis in children.

Dr. Peltola reports receiving consulting fees from the Serum Institute of India and lecture fees from Novartis. Dr. Pääkkönen reports receiving travel support from Synthes. No other potential conflict of interest relevant to this article was reported.

Disclosure forms provided by the authors are available with the full text of this article at NEJM.org.

We thank Pentti Kallio, M.D., for orthopedic consultation regarding the patient described in the vignette; Richard Burton for checking the linguistic accuracy; and Juho Ajanki for assistance with an earlier draft of Figure 1.

REFERENCES

- Krogstad P. Osteomyelitis. In: Feigin RD, Cherry JD, Demmler-Harrison GJ, Kaplan SL, eds. Pediatric infectious diseases. 6th ed. Philadelphia: Saunders, 2009:725-42.
- Riise ØR, Kirkhus E, Handeland KS, et al. Childhood osteomyelitis-incidence and differentiation from other acute onset musculoskeletal features in a population-based study. BMC Pediatr 2008;8:45.
- Grammatico-Guillon L, Maakaroun Vermesse Z, Baron S, Gettner S, Rusch E, Bernard L. Paediatric bone and joint infections are more common in boys and toddlers: a national epidemiology study. Acta Paediatr 2013;102(3):e120-e125.
- Gillespie WJ, Mayo KM. The management of acute haematogenous osteomyelitis in the antibiotic era: a study of the outcome. J Bone Joint Surg Br 1981;63-B:126-31.
- Syrgiannopoulos GA, Nelson JD. Duration of antimicrobial therapy for acute suppurative osteoarticular infections. Lancet 1988;1:37-40.
- Jaberi FM, Shahcheraghi GH, Ahadzadeh M. Short-term intravenous antibiotic treatment of acute hematogenous bone and joint infection in children: a prospective randomized trial. J Pediatr Orthop 2002;22:317-20.
- Prado SMA, Lizama CM, Peña DA, Valenzuela MC, Viviani ST. Short duration of initial intravenous treatment in 70 pediatric patients with osteoarticular infections. Rev Chilena Infectol 2008;25:30-6. (In Spanish.)
- Jagodzynski NA, Kanwar R, Graham K, Bache CE. Prospective evaluation of a shortened regimen of treatment for acute osteomyelitis and septic arthritis in children. J Pediatr Orthop 2009;29:518-25.
- Peltola H, Pääkkönen M, Kallio P, Kallio MJ. Short- versus long-term antimicrobial treatment for acute hematogenous osteomyelitis of childhood: prospective, randomized trial on 131 culture-positive cases. Pediatr Infect Dis J 2010;29:1123-8.
- Atkins BL, Price EH, Tillyer L, Novelli V, Evans J. Salmonella osteomyelitis in sickle cell disease children in the east end of London. J Infect 1997;34:133-8.
- Yagupsky P, Porsch E, St Geme JW III. *Kingella kingae*: an emerging pathogen in young children. Pediatrics 2011;127:557-65.
- Dartnell J, Ramachandran M, Katchburian M. Haematogenous acute and subacute paediatric osteomyelitis: a systematic review of the literature. J Bone Joint Surg Br 2012;94:584-95.
- Ju KL, Zurakowski D, Kocher MS. Differentiating between methicillin-resistant and methicillin-sensitive *Staphylococcus aureus* osteomyelitis in children: an evidence-based clinical prediction algorithm. J Bone Joint Surg Am 2011;93:1693-701.
- Liu C, Bayer A, Cosgrove SE, et al. Clinical practice guidelines by the Infectious Diseases Society of America for the treatment of methicillin-resistant *Staphylococcus aureus* infections in adults and children. Clin Infect Dis 2011;52(3):e18-e55. [Erratum, Clin Infect Dis 2011;53:319.]
- Butbul-Aviel Y, Koren A, Halevy R, Sakran W. Procalcitonin as a diagnostic aid in osteomyelitis and septic arthritis. Pediatr Emerg Care 2005;21:828-32.
- Pääkkönen M, Kallio MJ, Kallio PE, Peltola H. Sensitivity of erythrocyte sedimentation rate and C-reactive protein in childhood bone and joint infections. Clin Orthop Relat Res 2010;468:861-6.
- Arnold JC, Cannavino CR, Ross MK, et al. Acute bacterial osteoarticular infections: eight-year analysis of C-reactive protein for oral step-down therapy. Pediatrics 2012;130(4):e821-e828.
- Ceroni D, Regusci M, Pazos J, Dayer R, Kaelin A. Acute bone and joint infections in children: how much attention should be paid to persistent fever during intravenous antibiotic therapy? Rev Chir Orthop Reparatrice Appar Mot 2003;89:250-6. (In French.)
- Connolly LP, Connolly SA, Drubach LA, Jaramillo D, Treves ST. Acute hematogenous osteomyelitis of children: assessment of skeletal scintigraphy-based diagnosis in the era of MRI. J Nucl Med 2002;43:1310-6.
- Peltola H, Pääkkönen M, Kallio P, Kallio MJ. Clindamycin vs. first-generation cephalosporins for acute osteoarticular infections of childhood — a prospective quasi-randomized controlled trial. Clin Microbiol Infect 2012;18:582-9.
- Tetzlaff TR, Howard JB, McCracken GH, Calderon E, Larrondo J. Antibiotic concentrations in pus and bone of children with osteomyelitis. J Pediatr 1978;92:135-40.
- Feigin RD, Pickering LK, Anderson D, Keeney RE, Shackelford PG. Clindamycin treatment of osteomyelitis and septic arthritis in children. Pediatrics 1975;55:213-23.
- Landersdorfer CB, Bulitta JB, Kinzig M, Holzgrabe U, Sörgel F. Penetration of antibacterials into bone: pharmacokinetic, pharmacodynamic and bioanalytical considerations. Clin Pharmacokinet 2009;48:89-124.
- Kaplan SL, Afghani B, Lopez P, et al. Linezolid for the treatment of methicillin-resistant *Staphylococcus aureus* infection in children. Pediatr Infect Dis J 2003;22:Suppl:S178-S185.
- Chen CJ, Chiu CH, Lin TY, Lee ZL, Yang WE, Huang YC. Experience with linezolid therapy in children with osteoarticular infections. Pediatr Infect Dis J 2007;26:985-8.
- Summersgill JT, Schupp LG, Raff MJ. Comparative penetration of metronidazole, clindamycin, chloramphenicol, cefoxitin, ticarcillin, and moxalactam into bone. Antimicrob Agents Chemother 1982;21:601-3.
- Tetzlaff TR, McCracken GH Jr, Nelson JD. Oral antibiotic therapy for skeletal infections of children. II. Therapy of osteomyelitis and suppurative arthritis. J Pediatr 1978;92:485-90.
- Green JH. Cloxacillin in treatment of acute osteomyelitis. Br Med J 1967;2:414-6.
- Kaplan SL, Mason EO Jr, Feigin RD. Clindamycin versus nafcillin or methicillin in the treatment of *Staphylococcus aureus* osteomyelitis in children. South Med J 1982;75:138-42.
- Martínez-Aguilar G, Hammerman WA, Mason EO Jr, Kaplan SL. Clindamycin treatment of invasive infections caused by community-acquired, methicillin-resistant and methicillin-susceptible *Staphylococcus aureus* in children. Pediatr Infect Dis J 2003;22:593-8.
- Dubnov-Raz G, Scheuerman O, Chodick G, Finkelstein Y, Samra Z, Garty BZ. Invasive *Kingella kingae* infections in children: clinical and laboratory characteristics. Pediatrics 2008;122:1305-9.
- Messina AF, Namtu K, Guild M, Dumois JA, Berman DM. Trimethoprim-sulfamethoxazole therapy for children with acute osteomyelitis. Pediatr Infect Dis J 2011;30:1019-21.
- Sherman JW, Conte JE Jr. Ceftriaxone treatment of multidrug-resistant *Salmonella* osteomyelitis. Am J Med 1987;83:137-8.
- Bradley JS, Jackson MA, Committee on Infectious Diseases, American Academy of Pediatrics. The use of systemic and topical fluoroquinolones. Pediatrics 2011;128(4):e1034-e1045.
- Ebong WW. Acute osteomyelitis in Nigerians with sickle cell disease. Ann Rheum Dis 1986;45:911-5.
- Mantadakis E, Plessa E, Vouloumanou EK, Michailidis L, Chatzimichael A, Falagas ME. Deep venous thrombosis in children with musculoskeletal infections: the clinical evidence. Int J Infect Dis 2012;16(4):e236-e243.
- Dich VQ, Nelson JD, Haltalin KC. Osteomyelitis in infants and children: a review of 163 cases. Am J Dis Child 1975;129:1273-8.
- Vaughan PA, Newman NM, Rosman MA. Acute hematogenous osteomyelitis in children. J Pediatr Orthop 1987;7:652-5.
- Penberthy GC, Weller CN. Chemotherapy as an aid in the management of acute osteomyelitis. Ann Surg 1941;114:129-46.
- Kenney WE. The prognosis in acute hematogenous osteomyelitis with and without chemotherapy. Surgery 1944;16:477-84.
- Harris NH. Some problems in the diagnosis and treatment of acute osteomyelitis. J Bone Joint Surg Br 1960;42-B:535-41.
- Cole WG, Dalziel RE, Leitel S. Treatment of acute osteomyelitis in childhood. J Bone Joint Surg Br 1982;64:218-23.
- Bocchini CE, Hulten KG, Mason EO

- Jr, Gonzalez BE, Hammerman WA, Kaplan SL. Panton-Valentine leukocidin genes are associated with enhanced inflammatory response and local disease in acute hematogenous *Staphylococcus aureus* osteomyelitis in children. *Pediatrics* 2006;117:433-40.
44. Belthur MV, Birchansky SB, Verdugo AA, et al. Pathologic fractures in children with acute *Staphylococcus aureus* osteomyelitis. *J Bone Joint Surg Am* 2012;94:34-42.
45. Bradley JS, Kaplan SL, Tan TQ, et al. Pediatric pneumococcal bone and joint infections. *Pediatrics* 1998;102:1376-82.
46. Martí-Carvajal AJ, Agreda-Pérez LH. Antibiotics for treating osteomyelitis in people with sickle cell disease. *Cochrane Database Syst Rev* 2012;12:CD007175.
47. Meller I, Manor Y, Bar-Ziv J, Torok G. Acute hematogenous osteomyelitis in children: long-term results of surgical treatment. *Orthop Rev* 1989;18:824-31.
48. Connolly SA, Connolly LP, Drubach LA, Zurakowski D, Jaramillo D. MRI for detection of abscess in acute osteomyelitis of the pelvis in children. *AJR Am J Roentgenol* 2007;189:867-72.
49. Vander Have KL, Karmazyn B, Verma M, et al. Community-associated methicillin-resistant *Staphylococcus aureus* in acute musculoskeletal infection in children: a game changer. *J Pediatr Orthop* 2009;29:927-31.
50. Stephens MM, MacAuley P. Brodie's abscess: a long-term review. *Clin Orthop Relat Res* 1988;234:211-6.

Copyright © 2014 Massachusetts Medical Society.